

**Título: Management of Squamous Cell Carcinoma of the Conjunctiva: Case Report**

**Nome do(s) autor(es):** *Patrick Frensel M Tzelikis.*

**Nome da instituição:** *Hospital Oftalmológico de Brasília - HOB.*

**Palavras-chave:** Squamous Cell; Carcinoma; Corneal; Chemoterapy .

### Case Report

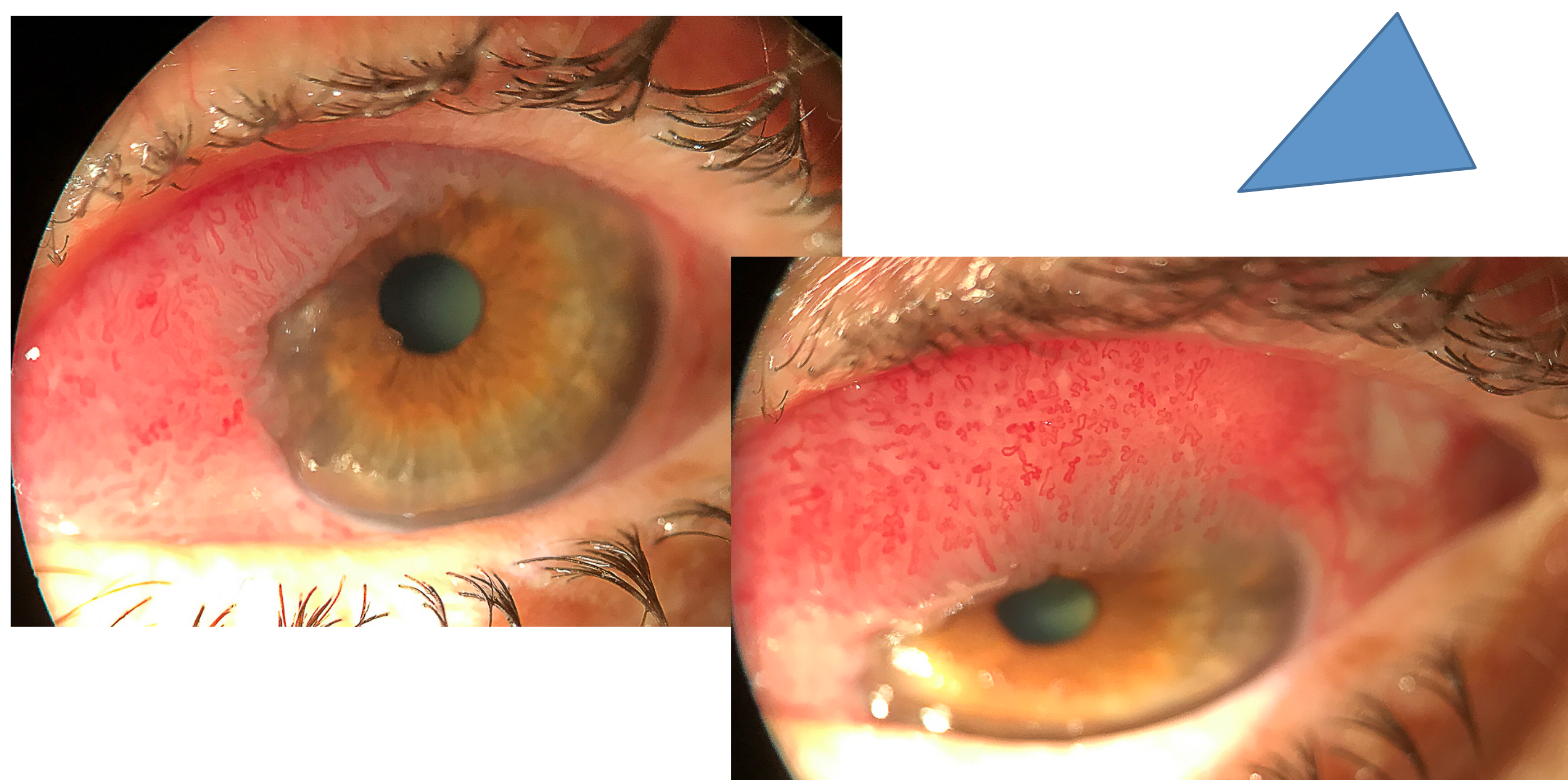
#### History

68-year-old white man was referred by an outside ophthalmologist for evaluation of a lightly pigmented mass at the nasal and superior limbus of his left eye.

#### Past Ocular History:

- His past ophthalmology history was markable by the use of topical 0.04% mitomycin C for 2 cycles (1 week on and 1 wekk off). At the end of the 2th cycle, there was no evidence of improvement. Referred!
- No prior history of contact lens use, trauma, or ocular surgery.

**Medical History:** significant for hypertension.

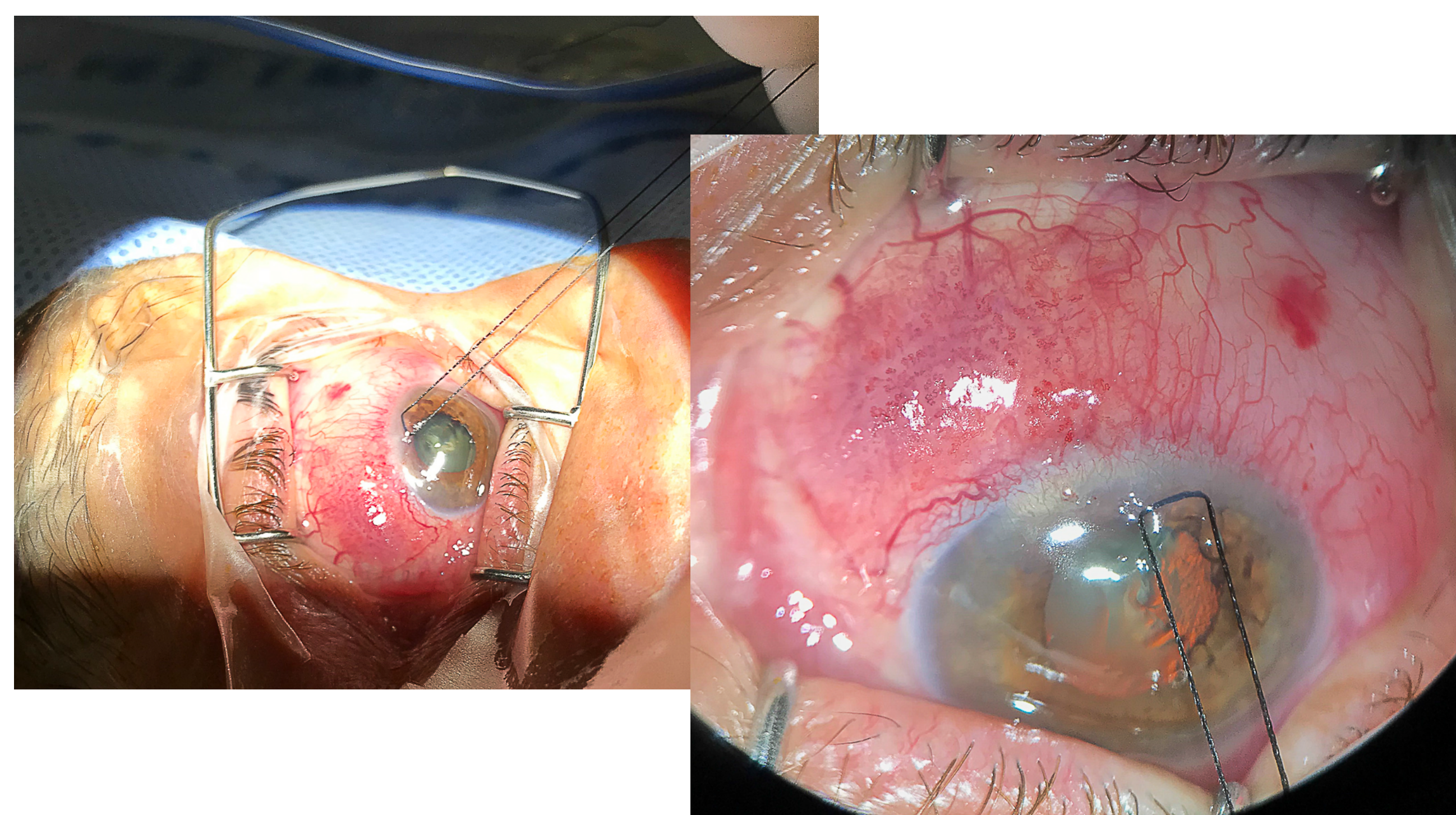


#### Ocular Exam

UDVA:	CDVA
OD: 20/40	OD: 20/20 +0.25 -0.75 X 90
OS: 20/50	OS: 20/25 +0.50 -1.25 X 85
EOM: full OU	Color plates: 12/12 ishihara
IOP: 14 mmHg OU	

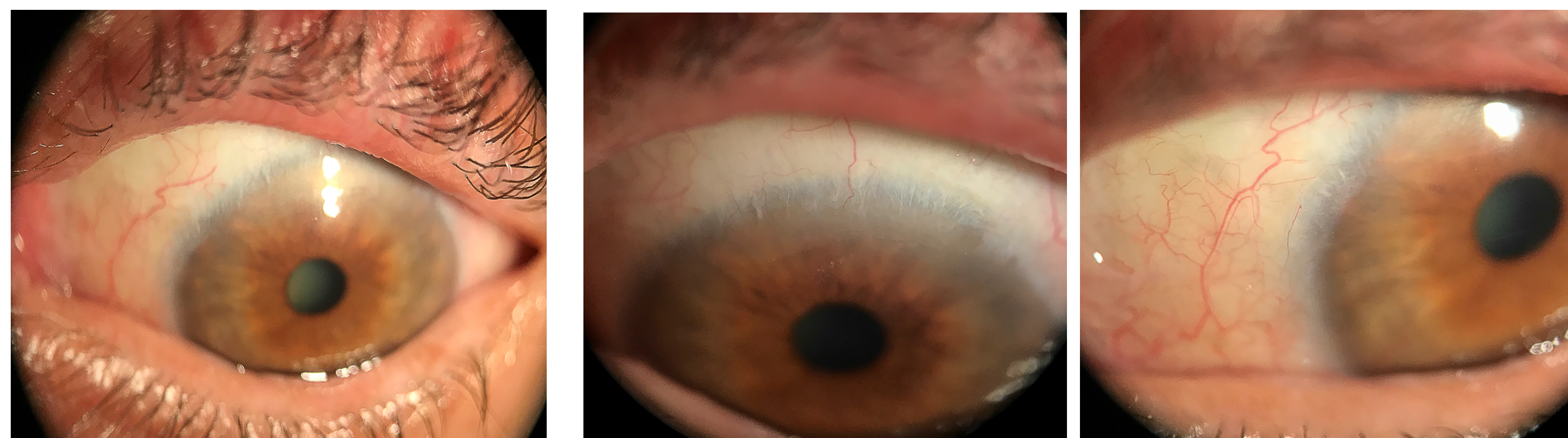#### Biomicroscopy

- Conjunctiva: large gelatinous tumor involving the nasal limbus OS
- Cornea: clear OU
- Anterior chamber: deep and free of cells and flare OU
- The iris was normally pigmented
- Crystalline (lens): mild nuclear cataract OU.
- Fundus examination: normal OU



#### Treatment

- After management options were discussed, topical IFNa2b 1 million IU/ml 4 times a daily was initiated and maintained for 6 months.
- At the 6-month follow-up, there was a significant reduction in the tumor size.
- This time, patient underwent a wide tumor excisional biopsy with cryotherapy (double freeze-thaw) using traditional "no-touch" technique with 4-mm margins for conjunctival, alcohol with 2-mm margins for corneal, and adjacent conjunctival to cover the ocular defect.



#### Conclusion

Treatment options for large squamous cell carcinoma of the conjunctival can include a combination of chemotherapy and surgical excision

1- Shields CL, Naseripour M, Shields JA. Topical mitomycin C for extensive, recurrent conjunctival-corneal squamous cell carcinoma. Am J Ophthalmol 2002;133:601-606.  
2. Tunc M, Char DH, Crawford B, Miller T. Intraepithelial and invasive squamous cell carcinoma of the conjunctiva: analysis of 60 cases. Br J Ophthalmol 1999;83:98-103.  
3. McKelvie PA, Daniell M, McNab A, Loughnan M, Santamaria JD. Squamous cell carcinoma of the conjunctiva—a series of 26 cases. Br J Ophthalmol 2002;86:168-173.  
4. Pooler TRG. Conjunctival squamous cell carcinoma in Tanzania. Br J Ophthalmol 1999;83:177-179.  
5. Panda A, Sharma N, Titiyal JS, Ghose S, Sen S. Frozen section guided excision and lamellolamellar sclerokeratoplasty in squamous cell carcinoma of conjunctiva and cornea. In: Lass J, editor. Advances in cornea. New York: Plenum, 1997: 143-149.  
6. Tseng SC, Prabhaswat P, Lee SH. Amniotic membrane transplantation for conjunctival surface reconstruction. Am J Ophthalmol 1997;124:765-774.  
7. Tole DM, McKelvie PA, Daniell M. Reliability of impression cytology for the diagnosis of ocular surface neoplasia employing Biopore membrane. Br J Ophthalmol 2001;85:154-158.