

Issue 189 | January - February 2021

EMFOCO

OFTALMOLOGIA

Associação Brasileira de Catarata e Cirurgia Refrativa
Brazilian Society of Cataract and Refractive Surgery



BRASCRS 2021: NEW DATE!

The in-person congress will take place
between August 18th and 21st in Salvador

Cover photo: hydropsia in
a 15-year-old patient



Keratoconus

When and how
do you use
Excimer Laser?
By Shady Awwad



Visual field

Virtual Reality
with Advanced
Vision Analyzer
(AVA), by Ashvin
Agarwal



Artificial Intelligence

Understanding
its use in
Ophthalmology,
with Alessandro
Jammal

SUMMARY



This is a bimonthly publication of the Brazilian Association of Cataract and Refractive Surgery (ABCCR/BRASCRS), Praia do Flamengo, 66, Block B, rooms 401 to 405 - Flamengo, Rio de Janeiro, RJ - CEP: 22210-903 - Phone: (21) 2225-2600 / www.brascrs.com.br

- General Editor**
Bruna Ventura
Vinicius Coral Ghanem
- Editorial board**
Adriana Tytium
Amar Agarwal
Ernesto Otero
Daniel Wasilewski
Isaac Ramos
Marcelo Occhiutto
Rachel Gomes
Renata Rezende
Wilson Takashi Hida
- Cataract Commission**
Daniel Wasilewski
Isaac Ramos
Marcelo Occhiutto
Rachel Gomes
Renata Rezende
Wilson Takashi Hida
- Refractive Surgery Commission**
Daniel Wasilewski
Emilio Torres-Netto
Glauco Henrique Mello
Isaac Ramos
Jackson Barreto Junior
Marcony Santhiago
Larissa Gouvêa
- Cornea Commission**
Aline Moriyama
Gustavo Amorim Novais
Jefferson Lautert
Nicolas Cesário Pereira
Victor Antunes
- OF Glaucoma**
Fábio Bernardi Daga
Victor Cvintal
- OF Retina**
Richard Hida
- OF Ocular Surface**
Richard Hida
- Resident Section**
Victor P. Simocelli
- EyeWorld**
Marcony Santhiago
- International Editorial Council**
Adriana Tytium
Amar Agarwal
Ernesto Otero
Filomena Ribeiro
Ike Ahmed
Karoline Maia Rocha
Liliana Werner
Marian S Macsai
Roberto Pineda
- Editorial Production and Printer**
Betina Peppe
Communication and Editorial
Production
Avenida Malibu 260, 806/bloco 2,
Barra da Tijuca - Rio de Janeiro, RJ.
CEP: 22793-295
Phone and whatsapp:
+ 55 (21) 98807-1204
- News and general edition**
Betina Peppe Diniz
- Responsible graphic designer**
Cristiano Marsil
- Contact**
Oftalmologiaemfoco@gmail.com
- Printing**
Mais que Papel Artes Gráficas Ltda
Cássia Ramalho
Contact:
mais_que_papel@ibest.com.br
Phone:
(21) 99961-9737 and 96471-1030
- Responsible Journalist**
Betina Peppe Diniz - DRT 34.389/RJ



BOARD OF DIRECTORS 2020/2022

PRESIDENT Bruno Machado Fontes **VICE-PRESIDENT** Durval Moraes de Carvalho Jr, **GENERAL SECRETARY** Jonathan Clive Lake **1ST SECRETARY** Celso Takashi Nakano **GENERAL TREASURER** Mario José Carvalho **1ST TREASURER** Mario Cesar Araújo **FISCAL COUNCIL** Adriana dos Santos Forseto, Bruno Castelo Branco, Eduardo Ferrari Marback, Liang Shih Jung, Norma Allemann **DELIBERATIVE COUNCIL ABCCR/BRASCRS 2020/2022** Armando Stefano Crema, Bruno Machado Fontes, Canrobert Oliveira, Carlos Gabriel de Figueiredo, Carlos França Rangel, Carlos Heler Ribeiro Diniz, Carlúcio de Oliveira Andrade, Fernando L. C. Trindade, Flávio Rezende Dias, Homero Gusmão de Almeida, João Alberto Holanda de Freitas, José Eutrópio Vaz, Leonardo Akaishi, Marcelo Carvalho Ventura, Marco Antônio Rey de Faria, Miguel Ângelo Padilha, Newton Leitão de Andrade, Paulo Cesar Fontes, Pedro Paulo Fabri, Renato Ambrósio Junior, Ricardo Queiroz Guimarães, Tadeu Cvintal, Waldir Martins Portellinha, Walton Nosé (President) **COURSE COUNCIL** Cláudia Maria Francesconi, Edmundo José Velasco Martinelli, Marcelo Vieira Netto, Maria Cristina Ventura Leoratti, Maria Regina Catai Chalita, Mario Ursulino Machado Carvalho, Mauro Silveira de Queiroz Campos, Newton Kara José Junior, Roberto Pinto Coelho, Sergio Kwitko **PUBLICATION BOARD** Aline Moriyama (Cornea), Bruna Ventura (General Editor), Daniel Wasilewski (Cataract & Refractive), Emilio de Almeida Torres Netto (Crosslinking), Fábio Bernardi Daga (Glaucoma), Glauco Henrique Reggiani Mello (Refractive), Gustavo Amorim Novais (Cornea), Isaac Carvalho de Oliveira Ramos (Cataract & Refractive), Jackson Barreto Junior (Refractive), Jefferson Lautert, Larisa Gouvea, Marcelo Occhiutto (Cataract & Refractive), Marcony Rodrigues de Santhiago (Refractive & Eyeworld), Newton Kara José Jr. (Research Club/Ophthalmologist's Area), Nicolas Cesário Pereira (Cornea), Rachel Gomes (Cataract), Renata Atanasio de Rezende Bisol (Cataract), Richard Hida (Ocular Surface & Retina), Victor Andrihetti Coronado Antunes (Cornea), Victor Cvintal (Glaucoma), Victor P. Simocelli (OF Resident), Vinicius Coral Ghanem (General Editor), Wilson Takashi Hida (Cataract) **VIDEO DIRECTORS** Allan Cezar da Luz Souza, Amaryllis Avakian, Belquiz Rodrigues Nassaralla, Fabio Henrique Cacho Casanova, Frederico Franca Marques, João Marcelo de Almeida Gusmão Lyra, Leila Suely Gouvea José, Mauricio Arruda Camara Barros, Sergio Canabrava, Renato Klingelfus Pinheiro **SCIENTIFIC COMMISSION** Francisco Bandeira e Silva, Otavio Siqueira Bisneto, Patrick Frensel Tzelikis, Ramon Coral Ghanem, Ricardo Menon Nosé **SUBJECT AND INSTITUTIONAL RELATION COMMISSION** Celso Boianovsky, Daniel Alves Montenegro, Frederico Valadares de Souza Pena, Israel Rozemberg, Marco Antônio Rey de Faria, Reinaldo Ramalho **INTERNATIONAL RELATION COMMISSION** Bruna Ventura, Emilio de Almeida Torres Netto, Fernando L. C. Trindade, Gustavo Victor de Paula Baptista, Hamilton Moreira, Karoline Maia Rocha, Liliana Werner, Miguel Ângelo Padilha, Nicolas Cesário Pereira, Virgilio Centurion, Wilson Takashi Hida **INTERNATIONAL EDITORIAL COUNCIL** Adriana Tytium, Amar Agarwal, Ernesto Otero, Filomena Ribeiro, Ike Ahmed, Karoline Maia Rocha, Liliana Werner, Marian S Macsai, Roberto Pineda **BRASCRS RESIDENT** Daniela Barbosa Gemperli, Fabio Marques Vaz, Gabriel Bordin de Figueiredo, Henrique Saraiva Padilha Velasco, Iris de Souza Yamane, Juliana Almodin, Kátia Bottós, Marcella Quaresma Salomão, Rodrigo de Pinho Paes Barreto, Victor P. Simocelli **GAC COMMISSION** Fernando Betty Cresta, Gildásio C. Almeida Jr., Juliana Bisco Ferreira da Silva e Freitas, Leonardo Correa Machado Pereira, Luciano Porto Bellini, Ricardo Barbosa Porto **CENTRAL DE CALCULADORAS ABCCR** Durval Moraes de Carvalho Junior, Felipe Marques de Carvalho Taguchi, Aydano Pamponet Machado, Aecio Dias, Andre Marcio Vieira Messias **INNOVATION IN OPHTHALMOLOGY COMMISSION** Bruno Lovaglio Caçado Trindade, Claudio Lovaglio Caçado Trindade, Leiser Franco de Moraes Filho, Newton Andrade Junior, Renan Ferreira Oliveira, Ricardo Augusto Paletta Guedes, Paulo Schor **BRASCRS ACADEMY & WEBMEETINGS SITE COMMISSION** Bernardo Menelau Cavalcanti, Frederico Bicalho Dias da Silva, Filipe B Accioly de Gusmão, Rafael Freire Kobayashi **COMUNICATION COMMISSION** Alexandre Hasler Principe de Oliveira, Antônio Francisco Pimenta Motta, Breno Barth, Daniel Moon Lee, Gilberto Akio Shimoda, Lizabel Vieira Barbosa Gemperli, Paulo Gilberto Jorge Fadel, Pedro Carlos Carricondo **FELLOWSHIPS CERTIFICATION COMMISSION** Francisco Grupenmacher, Gustavo Ricci Malavazzi, Marco Antônio Guarino Tanure, Renato Ambrósio Jr, Mauro Silveira de Queiroz Campos **SALVADOR 2021 CONGRESS PRESIDENTS** Amilton Sampaio, David Lucena, Newton Andrade Jr **RIO DE JANEIRO 2022 CONGRESS PRESIDENTS** Aileen Walsh Crema, Evandro Diniz, Marcella Quaresma Salomão

Affiliated



Obs.: The published articles reflect ideas and concepts defined by the authors and not necessarily positions of the editorial body or scientific truths.



BRASCRS 2021

**YES! OUR MEETING WILL HAPPEN,
AND IT WILL BE IN PERSON!**

Due to the Covid-19 situation in our country, the BRASCRS 2021 organizing committee has opted to change the data of the congress for everyone's safety.

The new date is

AUGUST 18TH TO 21ST
IN THE SAME PLACE - SALVADOR, BRAZIL

We look forward to seeing you!

www.brascrs2021.com.br

ABCCR
Associação Brasileira de Catarata e Cirurgia Refrativa

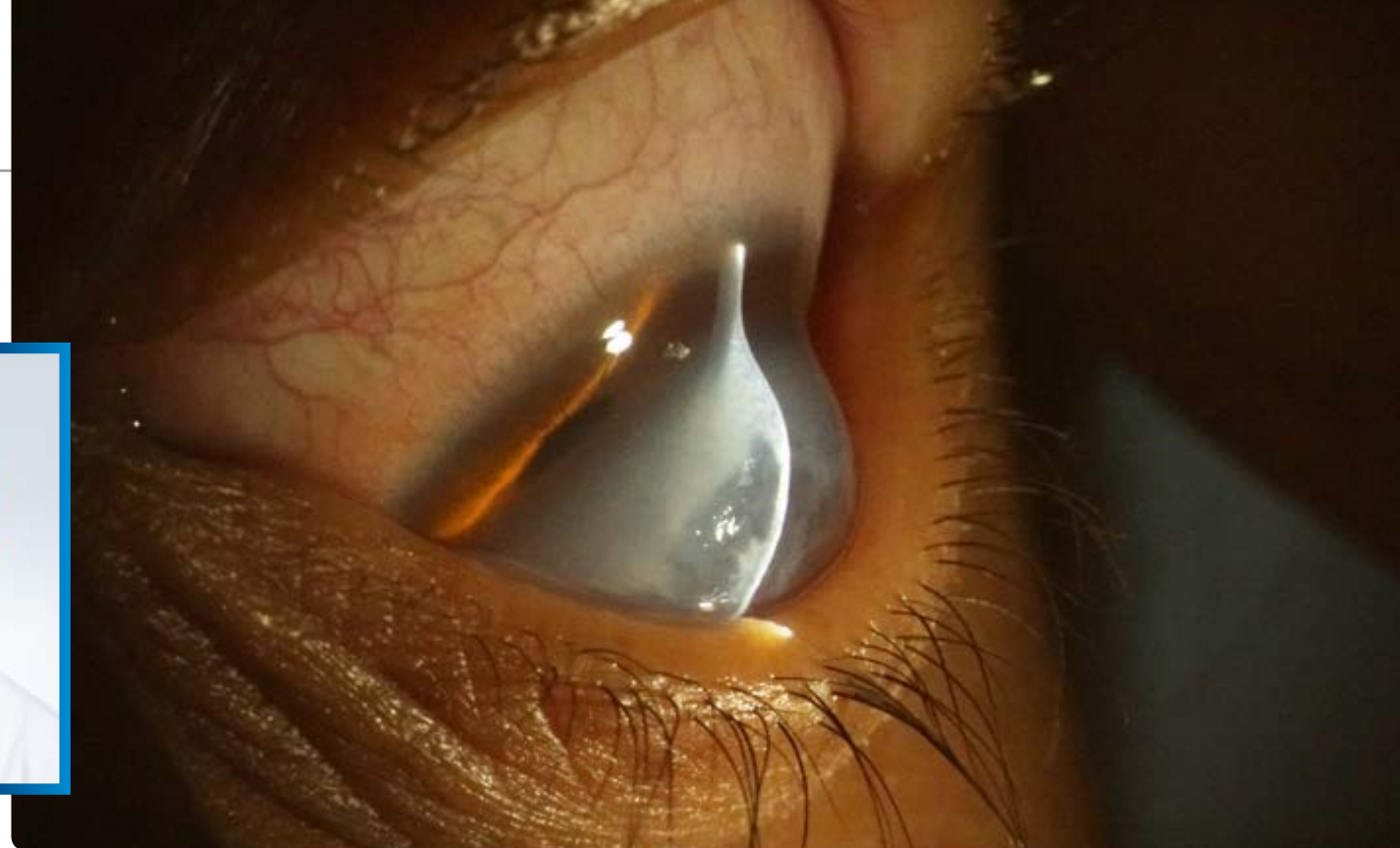

BRASCRS
Brazilian Association of Cataract and Refractive Surgery

COVER PHOTO

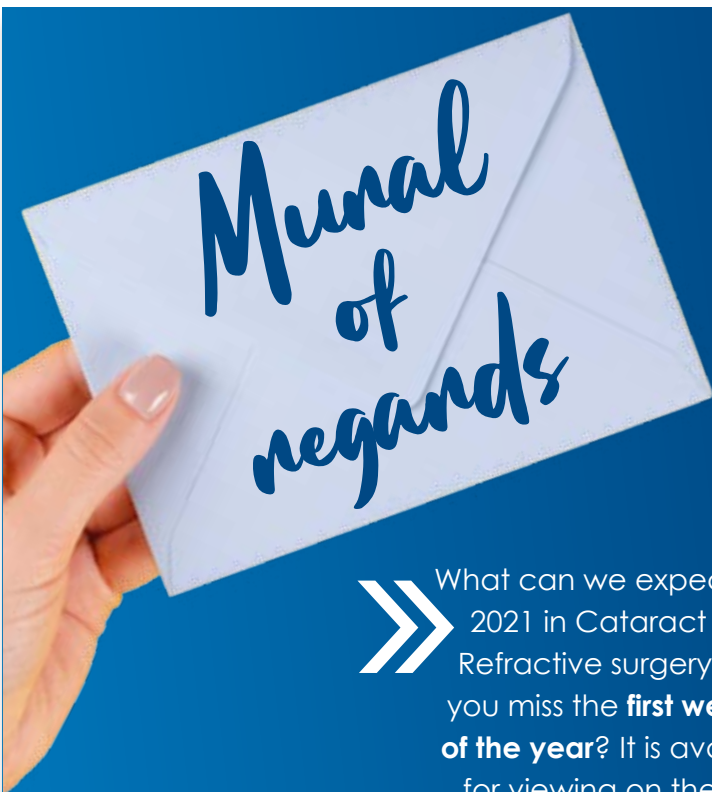

Author: Bruno Trindade
Ophthalmology professor at the Faculdade de Medicina Ciências (Feluma) in Belo Horizonte (MG).



A 15-year-old patient with an advanced keratoconus condition in both eyes. He had a corneal crosslinking surgery scheduled when he noticed sudden visual loss with pain, tearing, and foreign body sensation in the right eye. Upon examination, the patient had a visual acuity of hand movement near the face. It was possible to note the hydropsia with significant edema and diffusion with aqueous humor accumulation in enormous cysts in the interior of the corneal stroma. Due to the significant symptomatology,

we opted for the injection of SF6 gas diluted at 20% in the anterior chamber with drainage of the stromal cysts. The patient progressed well with a progressive corneal whitening. A year after the procedure, he presented a correct visual acuity of 20/80 and an improvement to 20/40 with the use of scleral contact lenses. This case illustrates the importance of rapid diagnosis of progression and treatment with crosslinking in patients with keratoconus to avoid these types of complications.



What can we expect from 2021 in Cataract and Refractive surgery? Did you miss the **first webinar of the year**? It is available for viewing on the site!

Doubts, opinions, suggestions?
Write to the journal Oftalmologia em Foco:
oftalmologiaemfoco@gmail.com

Renew your **2021 annuity** with BRASCRS. You gain access to cutting-edge content, discount on congress registration, among many other benefits. Just enter the site!

BRASCRS members also have **free access** to Eyeconnect International in 2021. For more information, send an email to atendimento@abccr.com.br.

Did you know that **OF digital is free** for all ophthalmologists? Just fill out the digital membership application and browse at your leisure! Invite colleagues to get to know and/or read your article: www.oftalmologiaemfoco.com.br.

**Access it.
Get to know it.
Enjoy it:**
www.brascrs.com.br

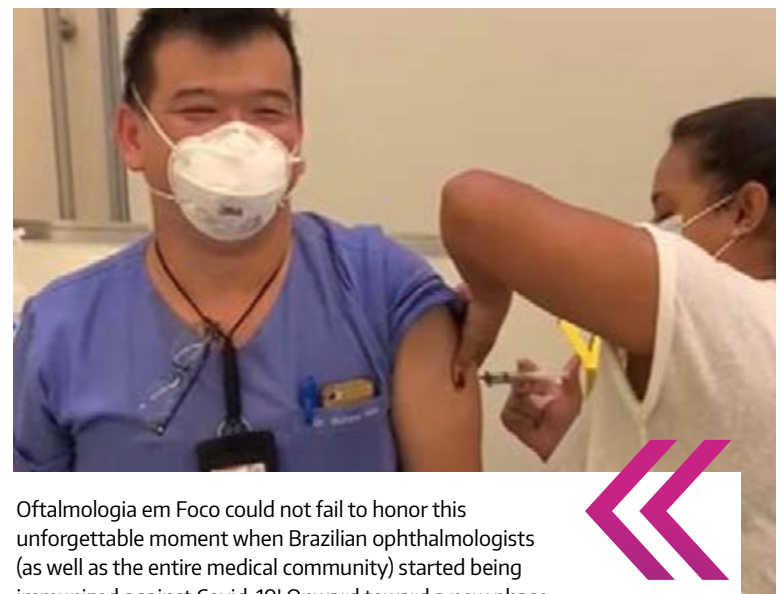

26

It seems like a lie, but soon, this will be a reality in the lives of thousands of Brazilian ophthalmologists. Learn all about BRASCRS 2021, which has been postponed until second half of the year so that we can guarantee an in-person reunion!

- 9 OF NEWS**
- 10 OF CATARACT**
Practical Guide in the management of intumescent white cataracts
- 15 OF CORNEA**
Femtosecond laser-assisted deep anterior lamellar transplantation
- 18 OF REFRACTIVE**
Case report: multimodal propedeutics in corneal ectasia
22 Excimer Laser surgery for keratoconus: when and how?
- 26 BRASCRS 2021**
Main attraction: your presence!
 - 28** Cornea day
 - 29** Glaucoma day
 - 30** Free theoretical courses
 - 32** GAC - The grand archive of cases
 - 33** Symposiums
 - 36** Business morning
 - 36** Phacomania
 - 37** Film festival
 - 37** Free theme
 - 38** Wet labs
 - 39** Conferences
 - 39** Awards
 - 40** Ophthalmology assistant course
 - 41** Closing remarks

- 42 OF GLAUCOMA**
Advanced vision analyzer (AVA): virtual reality perimeter
- 44 OF ARTIFICIAL INTELLIGENCE**
Understanding the use of artificial intelligence in ophthalmology
- 47 OF OCULAR SURFACE**
Keratoconus and ocular surface
- 50 OF RETINA**
Controversies in refractive lens exchange (RLE): point of view from retina surgeon
- 52 COVID-19**
Ophthalmological emergencies during the pandemic: my experience and the lessons that we've learned



09

Oftalmologia em Foco could not fail to honor this unforgettable moment when Brazilian ophthalmologists (as well as the entire medical community) started being immunized against Covid-19! Onward toward a new phase with renewed hope in overcoming this pandemic. Page 09.

Ex-Presidents

ABCCR/BRASCRS - since 2014



Sociedade Brasileira de CATARACT e Implantes Intraoculares - 1982/2014



Sociedade Brasileira de Cirurgia Refrativa - 1985/2014



Issue

“Paulo Cesar Fontes”

*president of SBII between 1987 and 1990,
and SBCR between 1996 and 1998*

In 1987, the junior ophthalmologist Paulo César Fontes assumed the presidency of the Brazilian Society of Intraocular Implantations (SBII). He accepted the position with much reluctance: “I was always a guy in the surgical center. I didn’t imagine myself managing a medical society”. His name was more than natural in the line of leadership succession, given his pioneering history in phacoemulsification surgery at the Hospital São Vicente de Paulo and his participation in the foundation and structuring of the institution he was about to lead.

Fontes accepted the challenge and returned his administration to the interiorization and dissemination of ideas and techniques across all of Brazil through SBII. He said that, at the time, he did not even spend a weekend at home, but went to several scientific symposiums and meetings held by Society in practically every region of the country.

Under his management, the IV International Symposium of SBII took place, which was struck by a “quasi-disaster”. The historic confiscation of Brazilians’ savings accounting, implemented by former president Fernando Collor de Melo’s economic plan, happened on the eve of the event. It was like being hit with a bucket of cold water. But they decided to keep the meeting and, surprisingly, the congress took place between April 25th and 28th, 1990 at the Hotel Nacional in Rio de Janeiro. It ended up being a success with many international speakers present alongside Brazilian physicians. At this event, one can even note the participation of the Refractive Society, which had been founded in 1985.

In 1996, PC Fontes was invited to run for the presidency of the Refractive Society in the institution’s first direct elections. He won the election, and together with Flavio Rezende at Cataract, held the Rio ’97 Cataract and Refractive Symposium, which took place on the 21st and 22nd of March at the Hotel Intercontinental, and the IV International Congress of Cataract and Refractive Surgery, also at the Hotel Intercontinental from the 13th and 16th of May 1998.

PC Fontes is the father of Bruno Fontes, the current president of The Brazilian Association of Cataract and Refractive Surgery (ABCCR/BRASCRS).

These and other stories are told in the book, “Brazilian Association of Cataract and Refractive Surgery, the History”. Access and read it: www.brascrs.com.br.




Paulo Cesar Fontes, president of SBCR, during the North and Northeast regional symposium in 1997



Paulo Cesar Fontes and Carlos Gabriel Figueiredo at the III International Symposium of SBII and the I International Symposium of SBCR



A Medical team surrounds the first phacoemulsifier acquired in Brazil through the São Vicente de Paulo Hospital from Irmã Mathilde (back). From the left to the right, the ophthalmologists Argeo Barbieri (which would go on to acquire, years later, the second machine in the country), Edson Cavalcanti, Paulo Cesar Fontes, and Miquel A. Padilha



Mara Fontes, Robert Sinskey, PC Fontes, Gerald Faulkner (Hawaii, U.S.A.), at the start of SBII



Paulo César Fontes with his family. At the far left, seated, with his children on his lap, is BRASCRS president Bruno Fontes



Come be part of our history!

A word from the President



BRUNO FONTES
President of ABCCR/BRASCRS

Certainties and Uncertainties

We start 2021 as an “extension” of 2020. The same fears, restrictions, certainties, and uncertainties. Many living with the pain of the loss of friends and loved ones. Facing old and new challenges in the middle of this storm that is slow to pass.

We have had to possess great adaptability – we all have changed routines, activities, hobbies, and family and professional events. Professionally, by adapting the medical practice to the safety protocols and the remote/virtual events. But it feels as if it has all been left half done. There is no sense of satisfaction/fulfillment.

With all the challenges exposed, science has done its part (as it will always continue to do), bringing us increasing encouragement and hope. The so-called “light at the end of the tunnel” finally seems to be in sight. With that, the need for planning for post-Covid-19 again comes to mind: how do we catch up and meet the pent-up demand of those who need our professional care?

Then, we practically and objectively need to update ourselves scientifically and program which inputs, equipment, and technologies will be needed. We have a job that is essential and fundamental – an immense responsibility before society. We take care of the most important human sense: vision. It is imperative that we are up to date and prepared to provide the very best.

That said, I reaffirm the commitment of ABCCR/BRASCRS, as a scientific entity, with the diffusion and sharing of science in its areas of practice. We will continue spreading good practices and knowledge/information/technologies through events and virtual courses, traditional publications, and mainly, with our in-person Congress in Salvador. We did not give up on our event. But we have had to postpone it until the second half of the year in hopes of vaccinating a wider population, as it is our responsibility for providing greater safety for all.

In the hope that I can meet most of my colleagues and friends from Brazil and the world – preferably vaccinated! – we are preparing a vast, deep, and complete program. You can be sure that we are working towards a safe, knowledge-rich, current, and fraternal event. We will be there for you and by you.

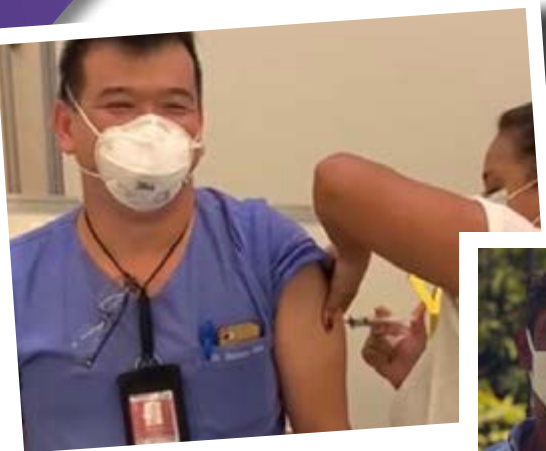See you soon!

Bruno Fontes




VACCINATED!

Oftalmologia em Foco is overjoyed to publish the images of ophthalmologists vaccinated against Covid-19, saluting the science and wishing for a friendlier reality to come true as soon as possible. Congratulations!



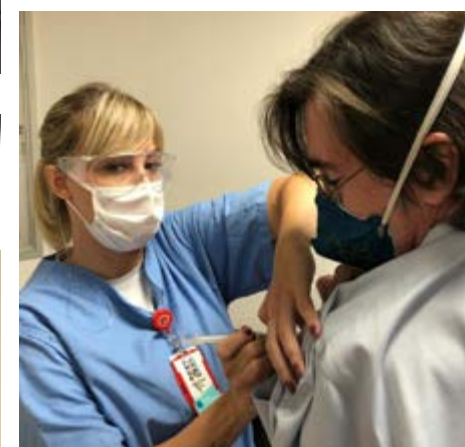
Richard Yudi Hida



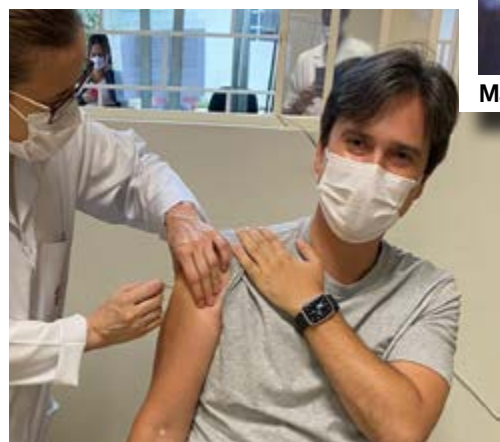Amaryllis Avakian



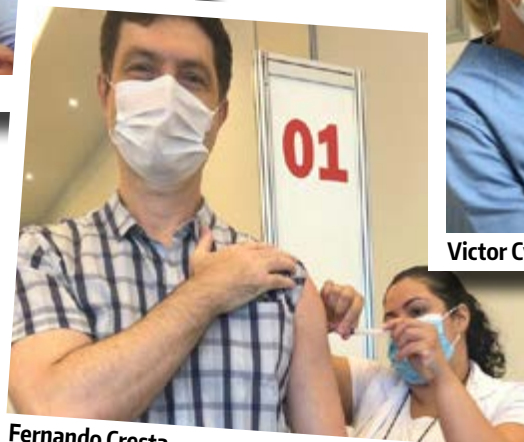
Marcony Santiago



Victor Cvintal



Glauco Mello



Fernando Cresta

AND SPEAKING OF SCIENCE, LOOK HOW NEAT!

Two editors of *Oftalmologia em Foco*, Marcony Santiago and Renato Ambrósio Junior, are among the most influential scientists in the world, according to a survey conducted by Stanford University in the U.S. The study called "Updated science-wide author databases of standardized citation indicators" took into consideration the citations based on data from Scopus, which updates the position of scientists in two

rankings: the impact of the researcher over the course of their career, and the impact of the researcher in a single year, in this case the year 2019.

Five other Brazilian ophthalmologists have made it on Stanford's list: João Marcello Furtado, José Álvaro Pereira Gomes, Mário Luiz Ribeiro Monteiro, Rubens Belfort Junior, and Vital Paulino Costa. In all, 161,441 scientists were listed, with 853 Brazilians among them.



Marcony Santiago



Renato Ambrósio Jr.

AUTOR

RICHARD YUDI HIDA

Ocular Surface Study Group - University of São Paulo (USP).
Surgical Optics - Federal University of São Paulo (Unifesp).
President of the Brazilian Laser and Ophthalmic Surgery Society (BLOSS), 2020.



Practical Guide in the management of

INTUMESCENT WHITE CATARACTS

This topic may not be useful until you come across this type of cataract in your practice! Learn about the best options for these kind of cataracts.

Today, we know that white cataracts can be intumescent and can cause increase of intracapsular pressure (Figure 3A and 3B). Most of the times, it behaves completely unexpectedly during some routine steps. Below are the best options for the management of these cataracts.

PROBLEMS AND DIFFICULTIES

- Possibility of increased pressure inside the lens (Figure 1).
- Difficulty in maintaining the integrity of the anterior edges of the capsulorhexis (Figure 2).
- Greater chance of complications (posterior capsule rupture).
- Difficulty in visualizing the capsule due to the absence of the red reflex (Figure 1).

SURGICAL TECHNIQUE AND MANUVRES FOR THE SUCCESS OF CAPSULORHEXIS

Several techniques are described to reduce complications of this type of cataract.

- Main incision.
- Trypan blue injection in the anterior chamber.
- Anterior chamber washing.
- Dispersive ophthalmic viscosurgical device (OVD) in the anterior chamber (Figure 3C).
- Apply mild pressure in the anterior capsule with cannula (Figure 3E and 3F).

SURGICAL TECHNIQUES TO AVOID COMPLICATIONS WITH THE CAPSULORHEXIS (FIGURE 4)

“The central mini-capsulotomy consists of performing multiple capsulotomies in the central 2 to 3 mm of the lens using a cystotome in order to relieve intracapsular pressure without compromising the edges of the anterior capsular opening, i.e., to avoid the capsularhexis from ‘running out’”

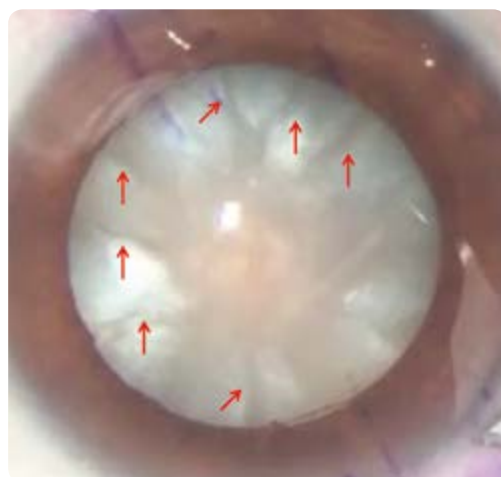

Figure 1 - Image of a completely white cataract. The presences of cryptas (red arrows) highly indicate the suspicion of increased intracapsular pressure

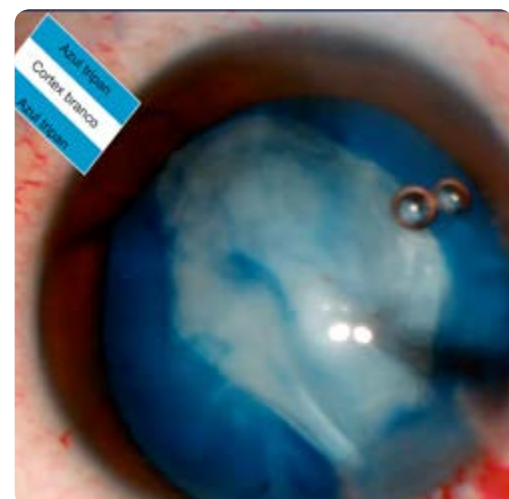


Figure 2 - Image of a totally white cataract with an anterior capsular rupture in form of an "Argentinian Flag"

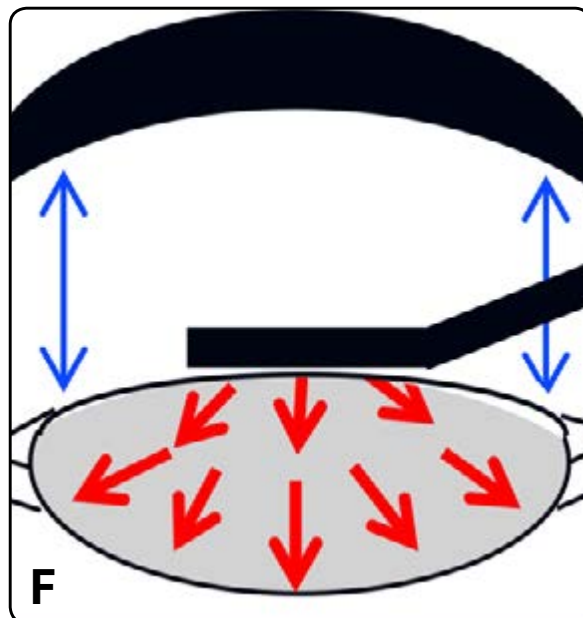
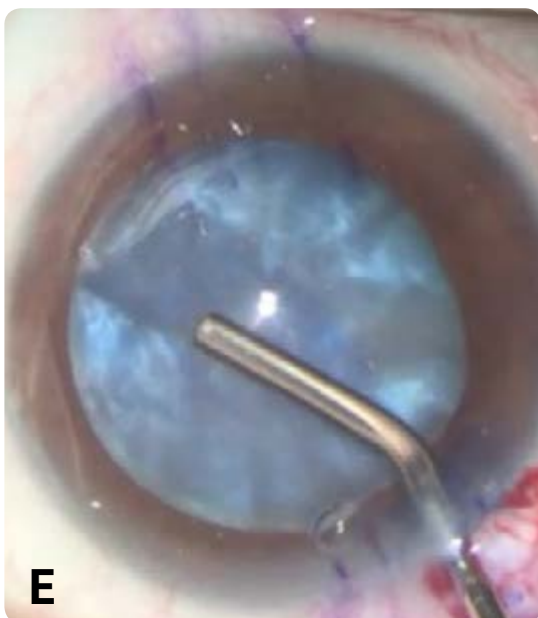
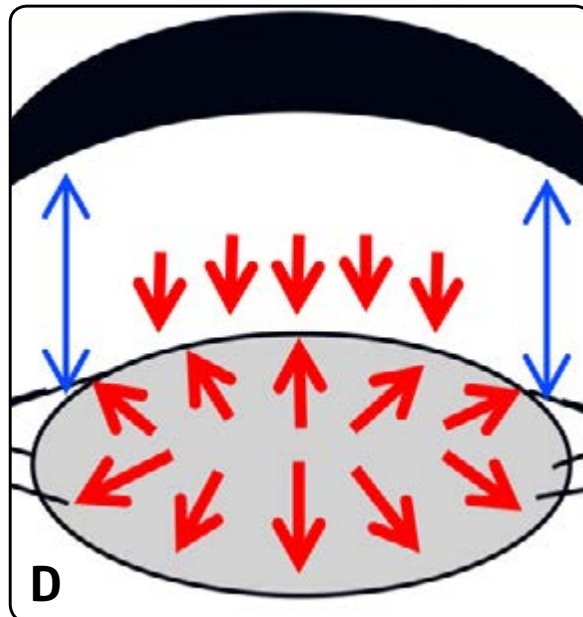
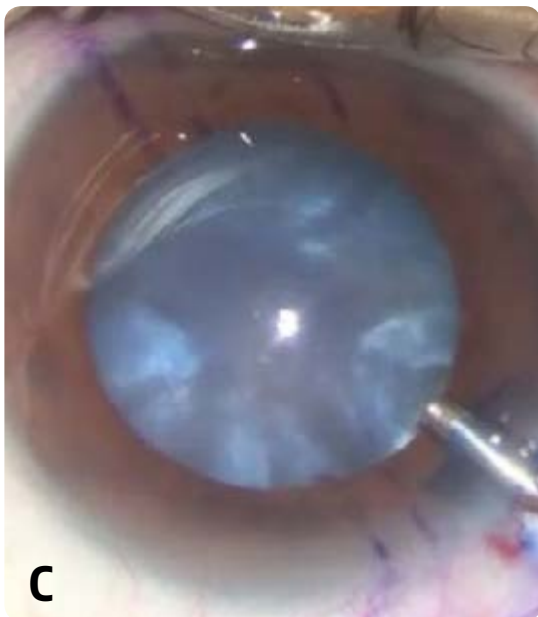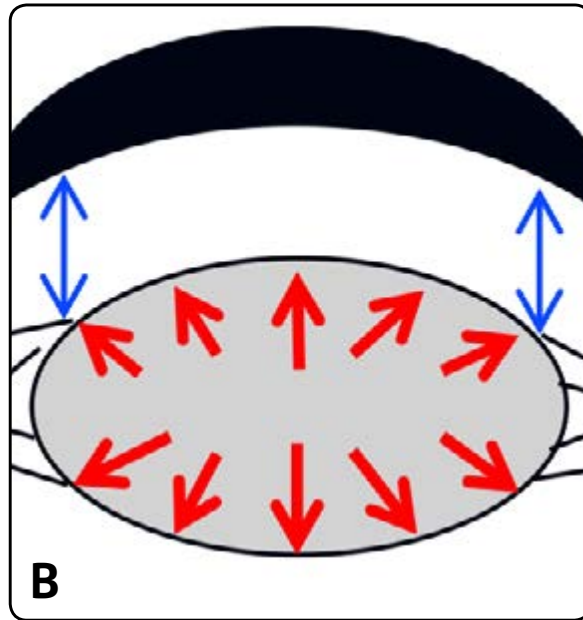
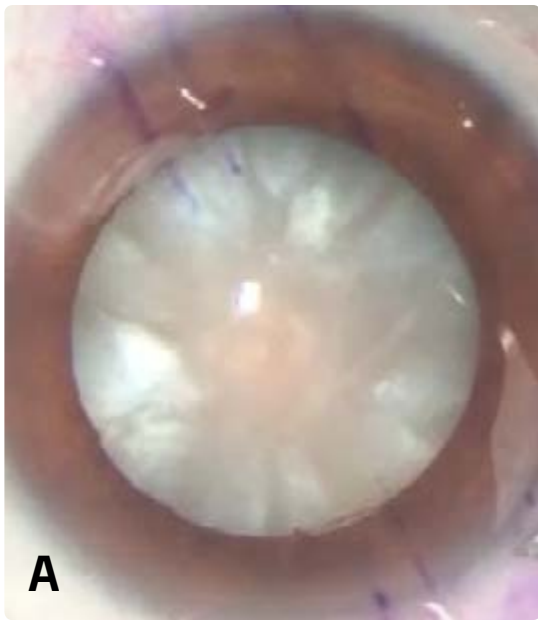


Figure 3 - A and B) Increase in intracapsular pressure due to excess material inside the crystalline lens. C and D) Injecting dispersive viscoelastic into the anterior chamber deepens the anterior chamber and slightly decreases anterior lens pressure (but not posterior lens pressure). E and F) Pressing the anterior capsule with a cannula allows the liquid to drain to the periphery of the crystalline lens and also checks whether or not the liquid can get in the way during the surgery

- Intracapsular aspiration.
- Mini-capsulorhexis.
- Visco-assisted capsulorhexis.
- Capsulorhexis with femtosecond laser.
- Central Mini-capsulotomy.

1 - ASPIRATION OF CAPSULAR BAG MATERIAL (FIGURES 5A AND 5B)

The technique consists of relieving intracapsular pressure, aspirating its material with a needle.

Surgical Technique:

- Check anterior chamber deepening and stabilization maneuvers (Figure 3).
- Through any incision, (choose the smallest), puncture and perforate the anterior capsule (Figure 5A).
- Quickly aspirate the inner material until stabilization (Figure 5B).
- Dispersive ophthalmic viscosurgical device (OVD) in the anterior chamber.
- Complete your routine capsulorhexis.

2 - MINI-CAPSULORHEXIS (FIGURE 6)

The technique consists of quickly performing a reduced size capsulorhexis to relieve intracapsular pressure.

Surgical Technique:

- Check the anterior chamber deepening and stabilization maneuvers (Figure 3).
- Through the main incision and using a capsule forceps (Utrata or Inamura), perform a small and central capsulorhexis, preferably quickly, to avoid the intracapsular pressure increasing and forcing the edges to the periphery of the lens

(Figure 6a).

- Dispersive ophthalmic viscosurgical device (OVD) in the anterior chamber.
- Complete your routine capsulorhexis.

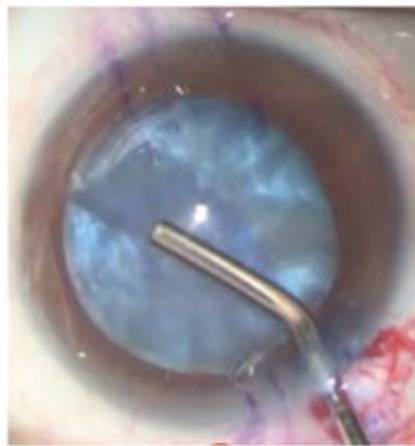
3 - VISCO-ASSISTED CAPSULORHEXIS (FIGURE 7)

The technique, shown by Dr. Robson Koyama, consists of performing a routine capsulorhexis and simultaneously injecting OVD through side port incision, with the purpose of increasing anterior chamber pressure during the abrupt decompression of the anterior capsule rupture and intracapsular material.

Surgical Technique:

- Check the anterior chamber deepening and stabilization maneuvers (Figure 3).

“White cataracts usually do not have an epinucleus susceptible to hydrodelineation, therefore, we must reduce the parameters of the vacuum and aspiration during the emulsification of the last nucleus fragments to avoid the rupture of the posterior capsule, if a ‘surge’ occurs”



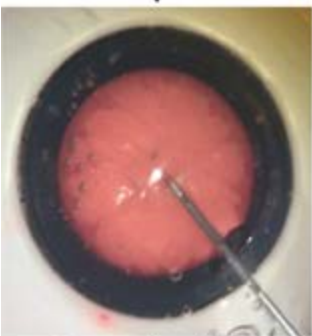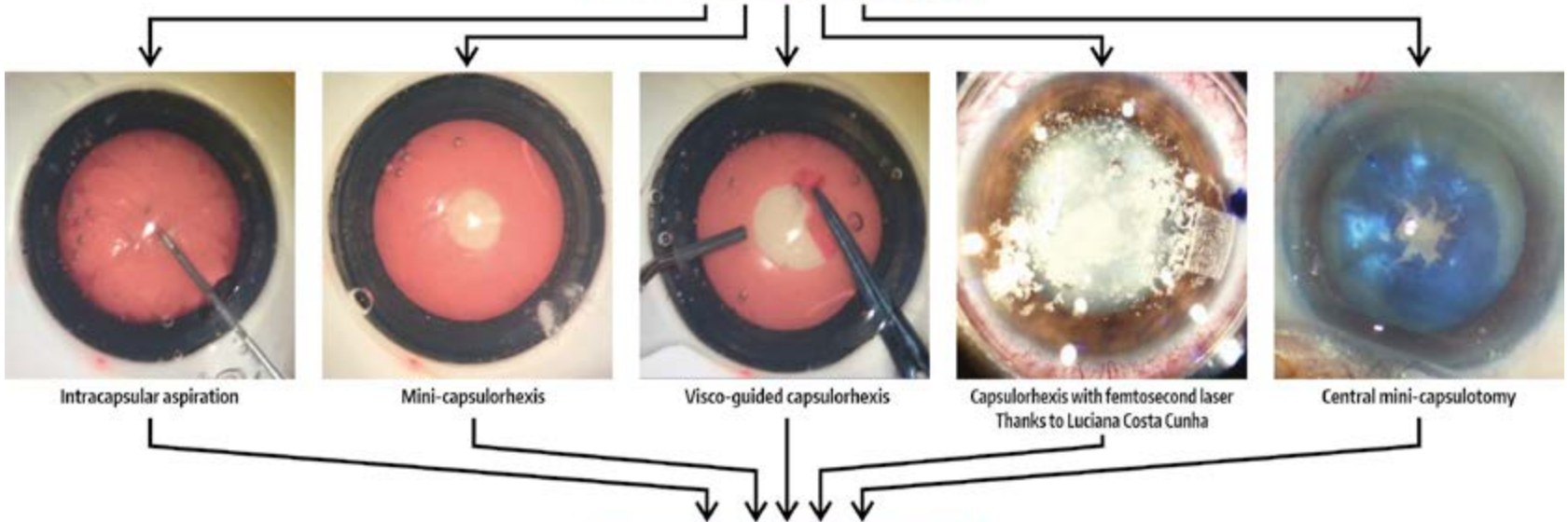
stable intraocular pressure.

Surgical Technique:


- Setup the femtosecond laser device for each surgeon’s routine surgery.
- Perform the routine capsulotomy.
- Explore all edges of capsulotomy for tags thorough main incision.
- Check the anterior chamber deepening and stabilization maneuvers.
- Complete and correct your routine capsulorhexis if necessary.

5 - CENTRAL MINI-CAPSULOTOMY

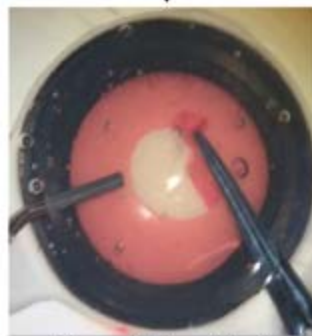
The technique consists of performing multiple capsulotomies in the central 2 to 3 mm of the lens using a cystotome in order to relieve intracapsular pressure without compromising the edges of the anterior capsular opening, i.e., to avoid the capsu-



Intracapsular aspiration



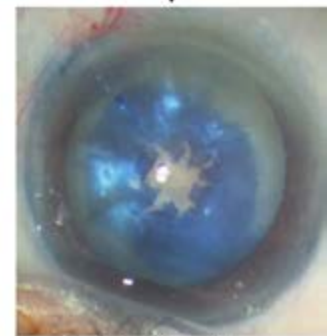
Mini-capsulorhexis



Visco-guided capsulorhexis



Capsulorhexis with femtosecond laser
Thanks to Luciana Costa Cunha



Central mini-capsulotomy

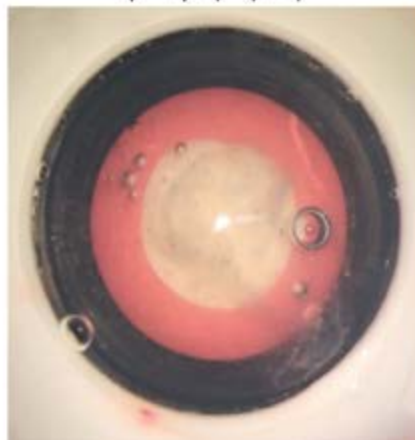


Figure 4

- With a cannula in the side port incision, perform the routine capsulorhexis through the main incision, simultaneously injecting OVD in the anterior chamber.

4 - CAPSULORHEXIS WITH FEMTOSECOND LASER

The technique consists of performing a capsulotomy using femtosecond laser before access of the anterior chamber, allowing

larhexis from “running out”. The technique described in congress videos and is the preferred technique of this article’s author (Figure 8).

Surgical Technique:

- Check the anterior chamber deepening and stabilization maneuvers.
- Using cystotome and through any inci-

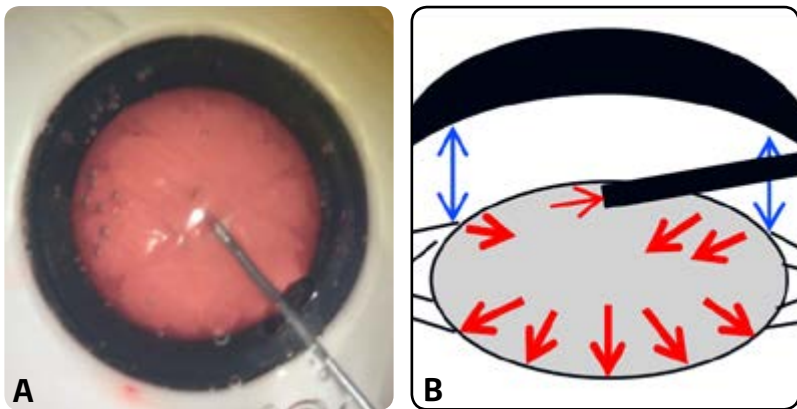


Figure 5

sion (choose the smallest), make random and quick punctures to perforate the anterior capsule several times (capsulotomy) in the central 2 to 3 mm of the lens, even with poor visualization due to lens material (Figures 7A, 7B and 8A).

- Inject dispersive OVD above the anterior capsule again (Figures 7C, 8B).
- Using a capsule forceps (Utrata or Inamura), grab any edge (flap) of the capsulotomy and complete your routine

capsulorhexis (Figures 7D to 7G) (Figures 8C to 8E).

White cataracts usually do not have an epinucleus susceptible to hydrodelineation, therefore, we must reduce the parameters of the vacuum and aspiration during the emulsification of the last nucleus fragments to avoid the rupture of the posterior capsule, if a “surge” occurs.

We would like to thank Dr. Carlos Gabriel Figueiredo for allowing us to use the images published in his article.

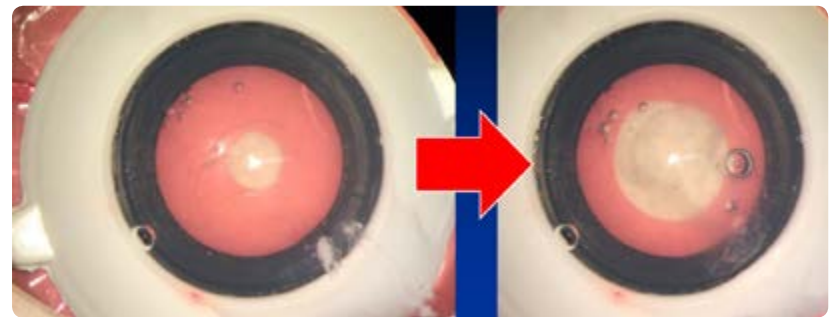


Figure 6

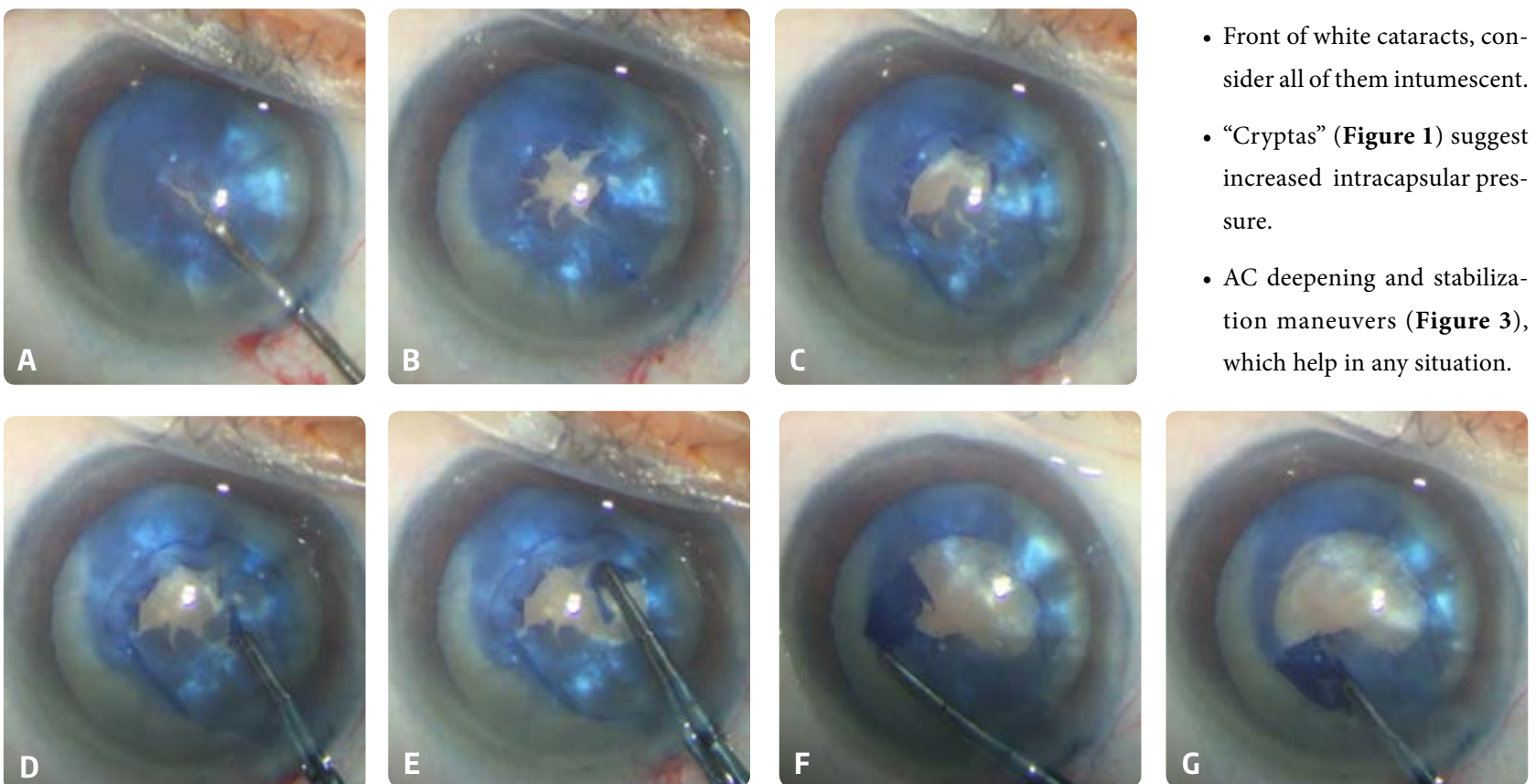
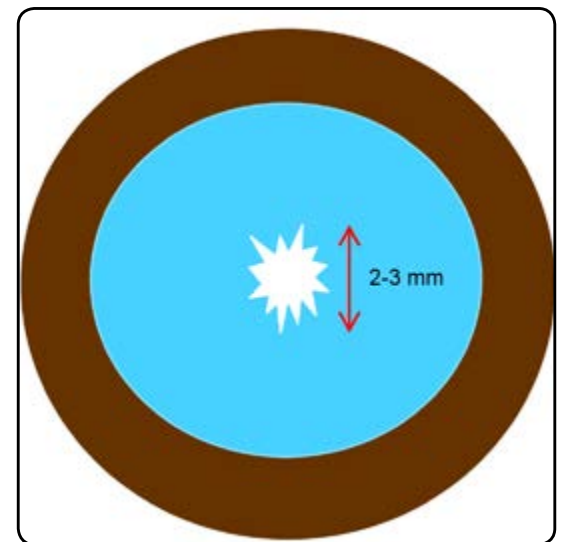


Figure 7

SUMMING UP

- Front of white cataracts, consider all of them intumescent.
- “Cryptas” (Figure 1) suggest increased intracapsular pressure.
- AC deepening and stabilization maneuvers (Figure 3), which help in any situation.

- The use of good quality viscoelastic helps in stabilizing the AC.
- Consider any of these techniques in these situations:
 - Intracapsular aspiration.
 - Mini-capsulorhexis.
 - Visco-guided capsulorhexis.
 - Capsulorhexis with femtosecond laser.
 - Central mini-capsulotomy.

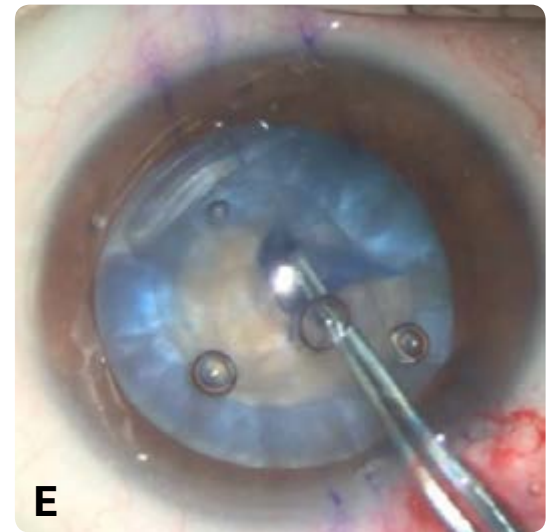
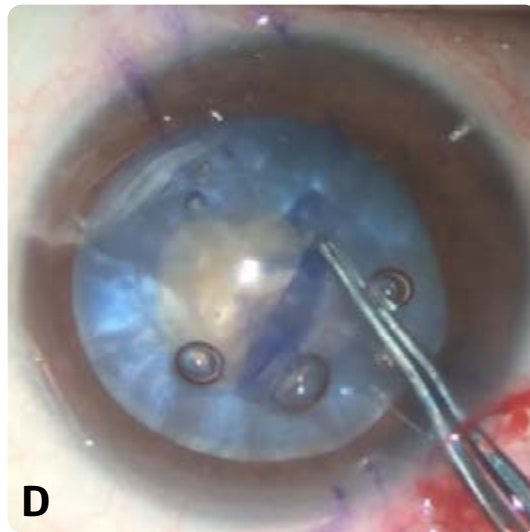
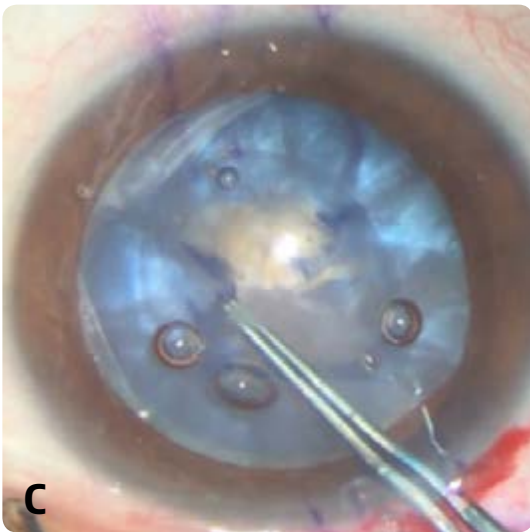
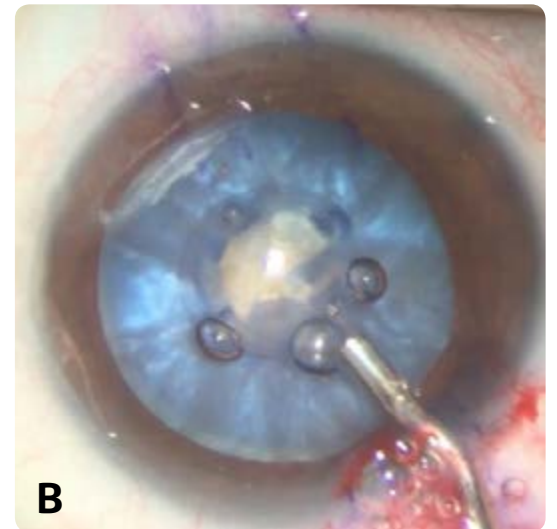
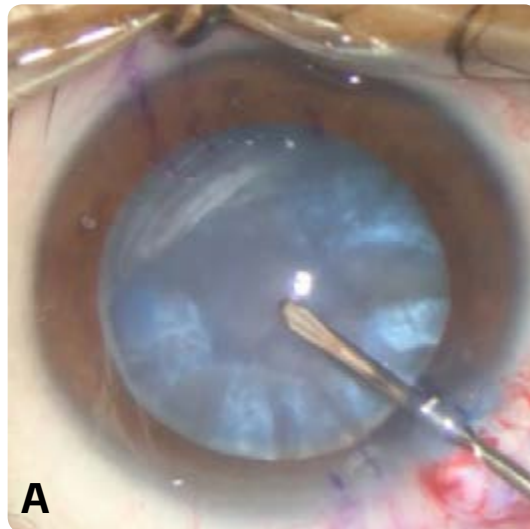



Figure 8



WEBINAR

BRASCRS

Current themes in **Cataract** and **Refractive Surgery** discussed the whole **month** by great specialists.

Join us!

www.brascrs.com.br/aovivo

AUTHORS

GABRIEL DE ALMEIDA FERREIRA

Cornea Department at Sadalla Amin Ghanem Hospital dos Olhos, Joinville, SC. Master's degree through Universidade Estadual Paulista (unesp), Botucatu, SP.

**RAMON CORAL GHANEM**

Cornea and Refractive Surgery Department at Sadalla Amin Ghanem Hospital dos Olhos, Joinville, SC. Doctorate through Universidade de São Paulo (USP), São Paulo, SP.

SECTION PUBLISHER
JEFERSON LAUTERT

Cornea Department at Sadalla Amin Ghanem Hospital dos Olhos, Joinville, SC.



“FSL is capable of performing innovative and precise corneal incisions, improving the stability and alignment of the interface, in addition to possibly reduced postoperative astigmatism”

Femtosecond laser-assisted

DEEP ANTERIOR LAMELLAR TRANSPLANTATION

INTRODUCTION

Deep Anterior Lamellar Keratoplasty (DALK) is currently the chosen technique for diseases that affect the cornea in which the endothelium is healthy, such as keratoconus, scarring, or anterior opacities.

To achieve a good visual quality postoperatively, it is fundamental to have a smooth interface between the donor and the recipient cornea, ideally without residual stroma, guaranteeing a good regularity and transparency. For that, we usually conquer the deep cleavage plane through air injection techniques in the deep stroma of the cornea, such as the big-bubble and pachy-bubble. However, these techniques depend on a long learning curve and are susceptible to failure.

With the advances in technology, femtosecond laser - FSL has also evolved and has increasingly become part of the routine of the cornea and refractive surgeon, bringing advantages to the intrastromal corneal ring surgery, LASIK (laser in-situ keratomileusis), among other procedures. As part of this development, we are now searching for ways to combine FSL with corneal transplantation.

FEMTOSECOND LASER IN PENETRATING TRANSPLANTATION

Penetrating transplantation is a surgery that already benefits from FSL, specifically for trephination. FSL is capable of performing

innovative and precise corneal incisions, improving the stability and alignment of the interface, in addition to possibly reduced postoperative astigmatism. The use of FSL allows the creation of several types of trephines shapes (top hat, zig-zag, mushroom), among others (**Figure 1**), with the great advantage of having a better fit between the donor and the recipient cornea, also increasing the contact surface between them.

FEMTOSECOND LASER IN DALK

As previously mentioned, the regularity of the interface between the donor and recipient cornea is fundamental for a good visual acuity in DALK, that is an interface without any residual stroma is desirable. Unfortunately, FSL is incapable of creating a smooth and regular surface in deep planes of the cornea, also it is not possible to perform the cutting plane precisely between the stroma and the Dua layer or Descemet membrane. Additionally, there is a risk of endothelial injury when applying the laser so close to it, as Liu et. al. demonstrated the lesion a study by applying a high energy laser at a distance of less than 150 μm . Fortunately, the most modern lasers use low energy and high frequency platforms, possibly not causing such damage, but there are still no studies analyzing these platforms.

The currently best technique to create the cleavage plane in DALK is through air injection in the deep stroma, initially performed

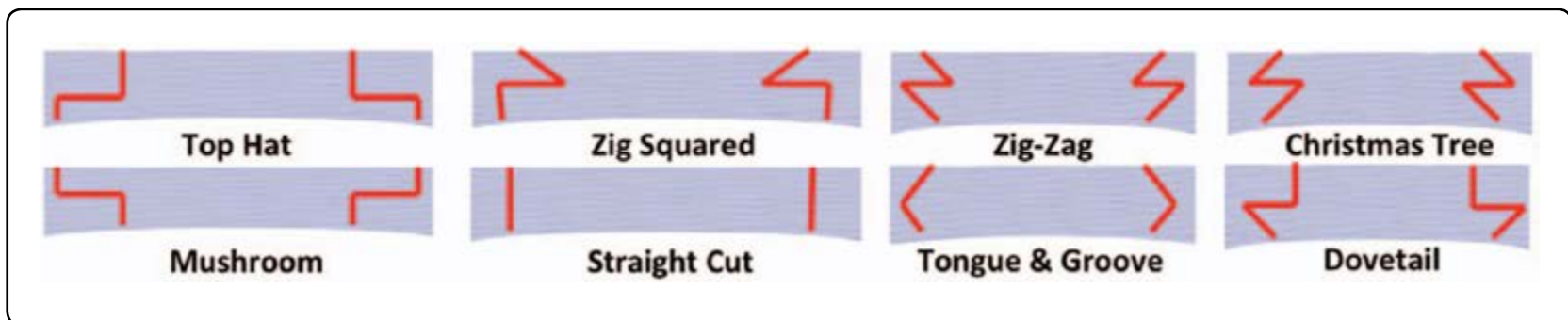


Figure 1 - Variety of possible trephination patterns with femtosecond laser

with the Big-Bubble technique. This technique was further improved with the use of corneal thickness measurement, either with the use of OCT (Optical Coherence Tomography) or intraoperative pachymeter.

The use of FSL has been studied to facilitate and standardize this fundamental surgical step and current research has been moving towards its use in trephination and in the execution of the fundamental surgical step, the injection of deep air to conquer the Big-Bubble. Buzzonetti et. al. was one of the first authors to head in this direction, associating the FSL with the concept of the Pachy-bubble, in which the deep tunnel for air injection is performed accordingly to the pachymetry of the cornea measured intraoperatively with a pachymeter. However, in his technique he used the pachymetry measured preoperatively by a Scheimpflug device to configure the creation of the tunnel through the FSL. In this study, the tunnel was carried out to a depth of 50 μm of the endothelium, with the Big-Bubble being achieved in 73% of cases. Probably the reason for this relatively low value was the use of preoperative exams that does not measure the thickness in real time.

Later, this technique was improved by Liu et. al. who used the intraoperative OCT coupled to the FSL device (Ziemer LDV Z8, Switzerland) for positioning the deep tunnel (**Figure 2**), achieving a big bubble in all 14 eyes of the published study. In his study he programmed the tunnel starting at 1 mm from the edge of the trephination (D_{t-s}) and 120 μm below the lamellar cut (D_{t-l}), with 3

mm in length (TL) and angle from 40 to 60 $^{\circ}$ (θ), reaching up to 50 μm of the endothelium (D_{t-dm}). The laser was programmed with cutting speed and energy of 7.5 mm/s and 150% for the lamellar cut, 7.5 mm/s and 120% for the tunnel and 40 mm/s and 150% for the trepanation, respectively, taking an average of 66 seconds for complete application.

Recently Lucisano et. al. published similar results using another FSL platform with integrated OCT (Victus, Bausch & Lomb, USA), managing to reach the type 1 Big-Bubble in 100% (11 eyes) of the cases of keratoconus patients. His technique was different from the previous one, as he used the laser to create a peripheral pocket deep in the cornea, through which tunneling for air injection was performed. In his study he made a pocket on the inner edge of the trepanation measuring 4.6 mm wide and 1.7 mm long at a depth 65 μm above the endothelium, through which he performed the

tunnel with a spatula up to 3 mm from the center of the cornea for injection of air. In the study, 1.70 μJ was used to cut the tunnel and 0.9 μm for trepanation.

CASE REPORT

A patient with previous Radial Keratectomy and LASIK performed in another service, had significant corneal ectasia (**Figure 3A**) and reduced visual acuity. FSL-assisted anterior lamellar corneal transplantation was performed associated with the Pachy-Bubble technique. Initially, we performed trepanation of the recipient cornea with the zig-zag cut pattern up to 100 μm of the endothelium (**Figure 3B**), being possible to observe the cut pattern in the slit lamp (**Figure 3C**). Then we performed the pachy-bubble technique, measuring the intraoperative corneal thickness at 1 mm from the trepanation and making an incision 60 μm shallower than the pachymetric measurement (**Figure 3D**). This incision was tun-

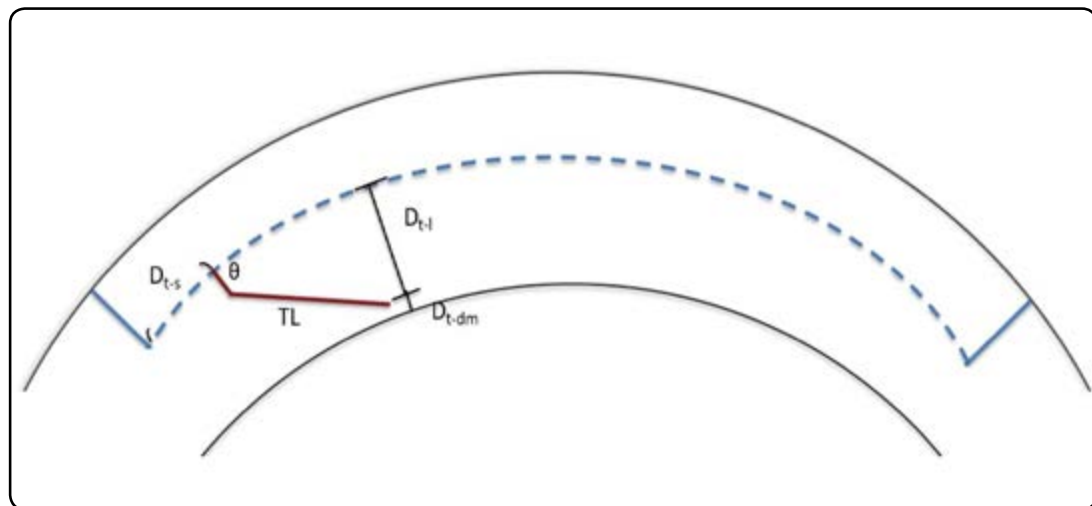


Figure 2 - Illustration of the surgical plan to perform FSL-assisted DALK. D_{t-s} : distance between the edge of the trephination and the start of the tunnel; θ : the angle of the tunnel; TL: extension of the tunnel; D_{t-l} : distance between the end of the tunnel and the lamellar cut; D_{t-dm} : distance between the end of the tunnel and the Descemet's membrane. (Source: Liu et. al., 2019)

neled and used for air injection, obtaining the Big Bubble with type 1 bubble (Figure 3E). The final aspect of the surgery shows an excellent apposition on the edge of the trephination between the corneas and in the OCT it is possible to see the pattern of the zig-zag cut well fitted between the two corneas (Figure 3F)

CONCLUSION

Significant advances have already been reached with FSL; however, we still have some significant limitations. The main one is the fact that the majority of FSL platforms use a flat surface for the cornea appplanation, causing a significant deformity in the posterior surface (Figure 2), which makes it difficult to accurately measure and cut at pre-endothelial planes. Additionally, there is a risk of performing an oval trephination in very prolated corneas, as is keratoconus corneas, caused mainly by the distortion resulted of flattening a very steeped cornea by a flat surface.

We believe that, in the future, FSL could be of great value to perform DALK, especially with its evolution and improvement of the current limitations (possibly by adopting a curved and liquid flattening interface), as it has the potential to standardize DALK's challenging steps, increasing the chance of big-bubble formation, and with the advantages of several patterns of trephination.

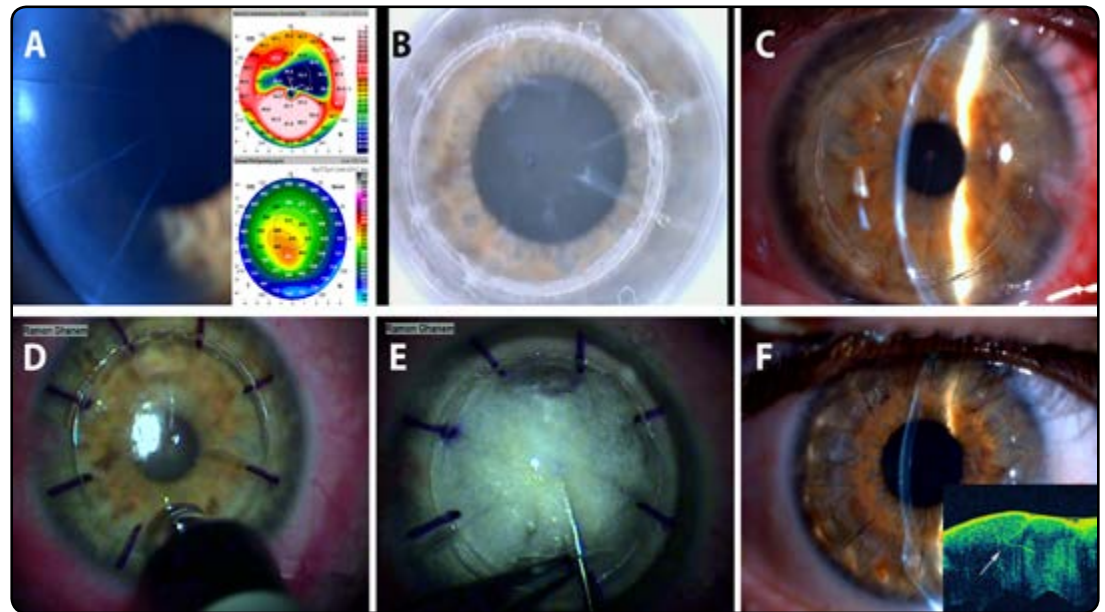


Figure 3 - (a) Biomicroscopy showing a transparent cornea with radial keratotomy associated with LASIK flap. Corneal tomography (Galilei G4, Ziemer) evidencing an inferior corneal ectasia with important local stepping and thinning. (b) FSL docking at the receptor's cornea, performing the trephination with zig-zag pattern. (c) Biomicroscopy right after FSL application evidencing the zig-zag trephination pattern. (d) Intraoperative image of the DALK performed with Pachy-Bubble technique, using a pachymeter to measure the corneal thickness 1 mm inside the trephination. (e) Big bubble (type 1 bubble) achieved with air injection. (f) Biomicroscopy at the first postoperative day showing a transparent cornea with good attachment between donor's and receptor's corneas. OCT image (Cirrus 4000, Zeiss) of the interface showing the zig-zag pattern.




Figure 4 - Screen capture of intraoperative real-time OCT imaging and configuration of the parameters in a patient with cornea scarring, showing the posterior distortion. Green line: lamellar cut; purple line: tunnel; blue line: thinnest corneal plane; T line: plane of tunnel tip; M line: plane of tunnel tip; tunnel length; distance between lines M and T; Dt-dm; distance between lines T and O (Source: Liu et. al., 2019)

REFERENCES

- Javadi MA, Mohammad-Rabei H, Feizi S, Daryabari SH. Visual Outcomes of Successful versus Failed Big-Bubble Deep Anterior Lamellar Keratoplasty for Keratoconus. *J Ophthalmic Vis Res.* 2016;11(1):32-6.
- Anwar M, Teichmann KD. Big-bubble technique to bare Descemet's membrane in anterior lamellar keratoplasty. *J Cataract Refract Surg.* 2002;28(3):398-403.
- Ghanem RC, Ghanem MA. Pachymetry-guided intrastromal air injection ("pachy-bubble") for deep anterior lamellar keratoplasty. *Cornea.* 2012;31(9):1087-91.
- Aristeidou A, Taniguchi EV, Tsatsos M, Muller R, McAlinden C, Pineda R, et. al. The evolution of corneal and refractive surgery with the femtosecond laser. *Eye Vis (Lond).* 2015;2:12.

- Marino GK, Santhiago MR, Wilson SE. Femtosecond Lasers and Corneal Surgical Procedures. *Asia Pac J Ophthalmol (Phila).* 2017;6(5):456-64.
- Chamberlain WD, Rush SW, Mathers WD, Cabezas M, Fraunfelder FW. Comparison of femtosecond laser-assisted keratoplasty versus conventional penetrating keratoplasty. *Ophthalmology.* 2011;118(3):486-91.
- Liu T, Zhang J, Sun D, Sui W, Zhang Y, Li D, et. al. Comparative study of corneal endothelial cell damage after femtosecond laser assisted deep stromal dissection. *Biomed Res Int.* 2014;2014:731565.
- Hosny M. Common complications of deep lamellar keratoplasty in the early phase of the learning curve. *Clin Ophthalmol.* 2011;5:791-5.
- Buzzonetti L, Laborante A, Petrocelli G. Standardized

- big-bubble technique in deep anterior lamellar keratoplasty assisted by the femtosecond laser. *J Cataract Refract Surg.* 2010;36(10):1631-6.
- Buzzonetti L, Petrocelli G, Valente P, Iarossi G, Ardia R, Petroni S, et. al. The Big-Bubble Full Femtosecond Laser-Assisted Technique in Deep Anterior Lamellar Keratoplasty. *J Refract Surg.* 2015;31(12):830-4.
- Liu YC, Wittwer VV, Yusoff NZM, Lwin CN, Seah XY, Mehta JS, et. al. Intraoperative Optical Coherence Tomography-Guided Femtosecond Laser-Assisted Deep Anterior Lamellar Keratoplasty. *Cornea.* 2019;38(5):648-53.
- Lucisano A, Giannaccare G, Pellegrini M, et. al. Preliminary Results of a Novel Standardized Technique of Femtosecond Laser-Assisted Deep Anterior Lamellar Keratoplasty for Keratoconus. *J Ophthalmol.* 2020;2020:5496162.

AUTHORS
RICARDO STURZENEKER

Institute of Ophthalmology, Rio de Janeiro. Post-graduation in Ophthalmology PUC (Pontifical Catholic University) - Rio de Janeiro. Fellowship in Cornea, External Diseases and Cataract from the Evangelical Hospital of Vila Velha - ES. Member of the Corneal Tomography and Biomechanics Studies Group of Rio de Janeiro.



NELSON SENA JR.

Department of Ophthalmology, the Federal University of the State of Rio de Janeiro - UNIRIO, University Hospital Gaffrée e Guinle - HUGG, Rio de Janeiro, RJ, Brazil. Corneal Biomechanics and Tomography Study Group of Rio de Janeiro (RJ), Brasil. Postgraduate Program in Medicine - Professional Master's Degree - the Federal University of the State of Rio de Janeiro - UNIRIO, University Hospital Gaffrée e Guinle - HUGG, Rio de Janeiro, RJ, Brazil.



RENATO AMBRÓSIO JR.

President of ISRS (2020-22). Adjunct Professor at UNIRIO and post-graduation affiliate professor at Unifesp. Clinical Direct of VisareRIO - Refracta Personal Laser. Founder and scientific coordinator of the Corneal Biomechanics and Tomography Study Group of Rio de Janeiro.



“The diagnostic advance with corneal tomography combined with biomechanics allowed for identifying cases of subclinical ectasias and enabled early propaedeutics”

Case report:

MULTIMODAL PROPEDEUTICS IN CORNEAL ECTASIA

SUMMARY

Purpose: Report a case of very asymmetric ectasia in an eye with grade I / II and a weak shape in the contralateral eye.

Methodology: A case report and literature review.

Results: The case demonstrates a 37-year-old male patient who reported a worsening in visual acuity at night six months ago. He showed an uncorrected visual acuity of 20/30 in the OD and 20/20 in the OS, with corrective lenses achieving visual acuity of 20/20 in the OD and 20/15 in the OS. Highly asymmetric ectasia was evidenced by grade I / II in the OD and a poor OS using multimodal analysis.

Conclusion: multimodal propaedeutics is of paramount importance, even in the presence of

mild and unspecific symptoms. The systematized analysis and approach allow for diagnosing subclinical diseases, making early treatment possible, and preventing potential aggravations.

Conflict of interests: Renato Ambrósio Jr. is a consultant for Oculus Optikgerate GmbH, Alcon, Zeiss, and Essilor.

INTRODUCTION

Keratoconus occurs through a biomechanical failure and is characterized by progressive corneal thinning. It is the most common ectatic disorder, and its appearance is asymmetrical, but the disease is invariably bilateral.¹⁻⁶

Its multifactorial etiology is still not fully clarified; however, studies show that its evolution is intimately linked to the genetic predisposition allied with environmental factors related to the

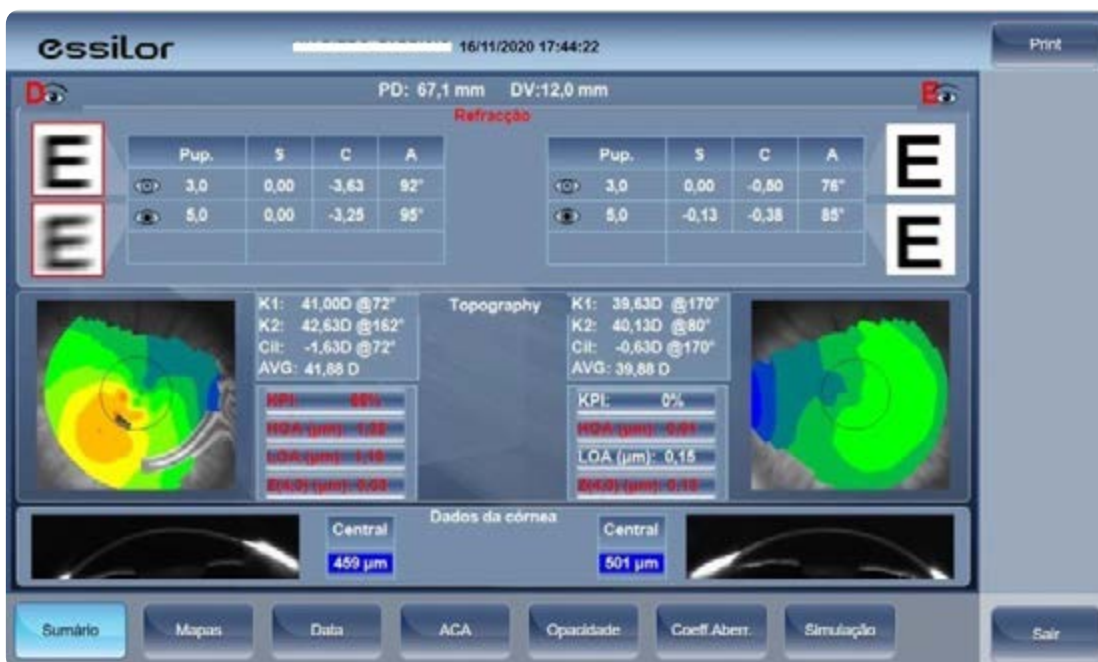

Figure 1 - Aberrometry and axial curvature map from anterior WAM performed through WAM 700 (Essilor™)

“Two Hit Hypothesis.”⁷⁻¹²

Multimodal propaedeutics ranging from the superficial study of corneal topography to the cornea’s biomechanical evolution has evolved exponentially. This is because of the need to evaluate ectasia’s risk after refractive surgery’s structural modification. To the detriment of this and the technological development, keratoconus diagnosis has been made earlier, characterized by its predisposition or susceptibility to develop ectasia as the examination’s objective.^{1,2,13-17}

The term forme fruste keratoconus refers to the predisposition for biomechanical decomposition to progress to ectasia.^{2,10,11} In these cases, integrated corneal tomography with biomechanical analysis performs an indispensable role in the diagnosis, which requires artificial intelligence to support the clinical decision.^{2,12,13,16-20}

CASE REPORT

The male patient, 37 years old, came in for a consultation complaining of worsening visual acuity at night. He did not present any comorbidities or a family history of any pathologies. He referred to rubbing his eyes with a preference for the OD.

The patient’s uncorrected visual acuity was 20/30 in the OD and 20/20 in the OS. With correction, his visual acuity reached 20/20 in the OD and 20/15 in the OS; refractometry showed +0.25 -3.5 x 85° in the OD and -0.25 -0.25 x 70° in the OS. The biomicroscopic examination proved Pterygium grade I in the OD’s nasal region, conjunctival nevus in the OS, and hyperemia papillae in the upper and lowered tarsal area of OU. Intraocular pressure was 13 mmHg in both eyes, and in the fundoscopic examination, no noteworthy changes were found.

Corneal topography, tomography, and aberrometry were performed through the Keratograph 5, Pentacam AXL Wave (Oculus GmbH; Wetzlar Germany), and Wave Analyzer Medical 700 WAM (Essilor; France) devices. The anterior axial curvature maps derived from the Placido discs and Scheimpflug were similar, using the Smolek/Klyce 1.5 D absolute scale. Asymmetric astigmatism pattern was observed in OU with a predominance in the OD, thinning along the inferior corneal temporal. Kmax measured at Pentacam AXL was 46.6 D in the OD and 41.8 D in the OS. In the topometric classification (TKC), keratoconus grade I/II in the OD and forme fruste in the OS were revealed (Figures 1, 2, 3).

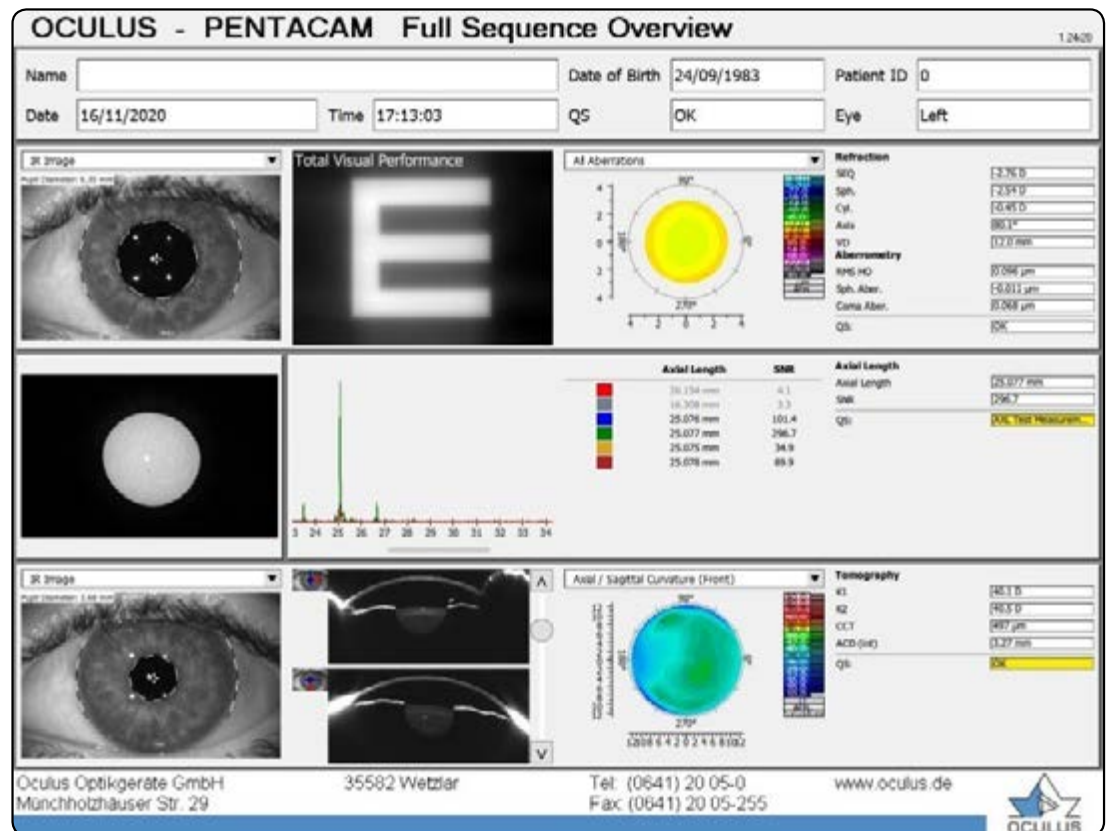
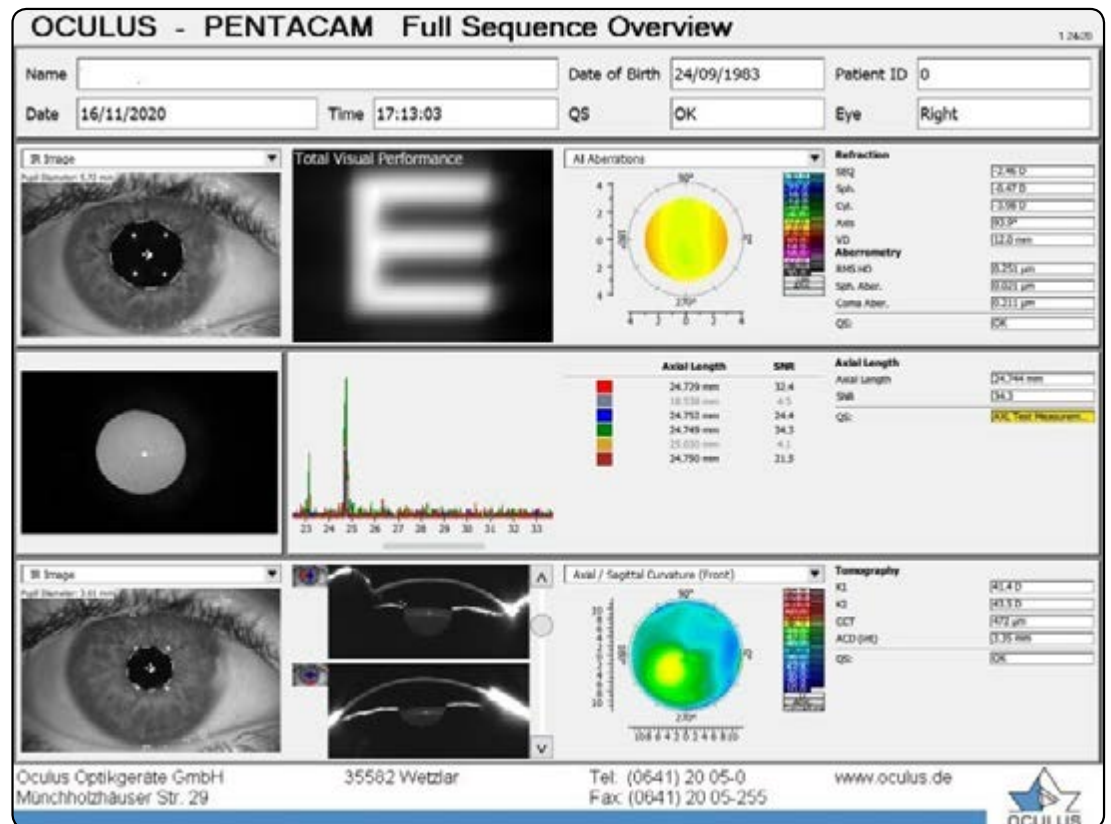


Figure 2 - Anterior axial map using rotational Scheimpflug device, Hartmann-Shack, and AXL aberrometry performed through Pentacam AXL-Wave™ device. Note the extreme asymmetry and many high-order aberrations, especially in the OD

asured at Pentacam AXL was 46.6 D in the OD and 41.8 D in the OS. In the topometric classification (TKC), keratoconus grade I/II in the OD and forme fruste in the OS were revealed (Figures 1, 2, 3).

The Belin/Ambrósio Display (BAD) for ectasias

showed altered anterior and posterior elevation maps in the OD and an altered elevation map in the OS. The biomechanical evaluation using Corvis ST (Oculus, Wetzlar, Germany) and Tomographic Biomechanical Index (TBI) were 1.0 in the OD and 0.63 in the OS, with a CBI of 1.0

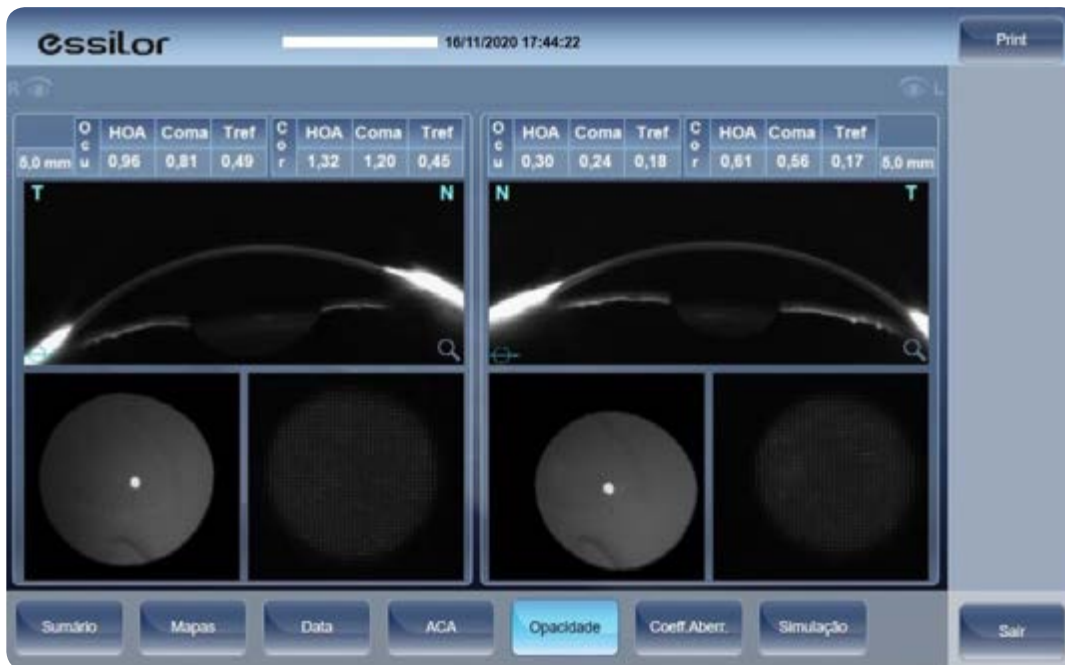


Figure 3 - Aberrometry using WAM 700 (Essilor™). Note the high order aberrations, especially under the scotopic conditions. (OD: total eyepiece - HOA 0.96, Coma 0.81, Trefoil 0.49; anterior cornea - HOA 1.32, Coma 1.20, Trefoil 0.45. OE: total eyepiece - HOA 0.30, Coma 0.24, Trefoil 0.18; anterior cornea - HOA 0.51, Coma 0.56, Trefoil 0.17)

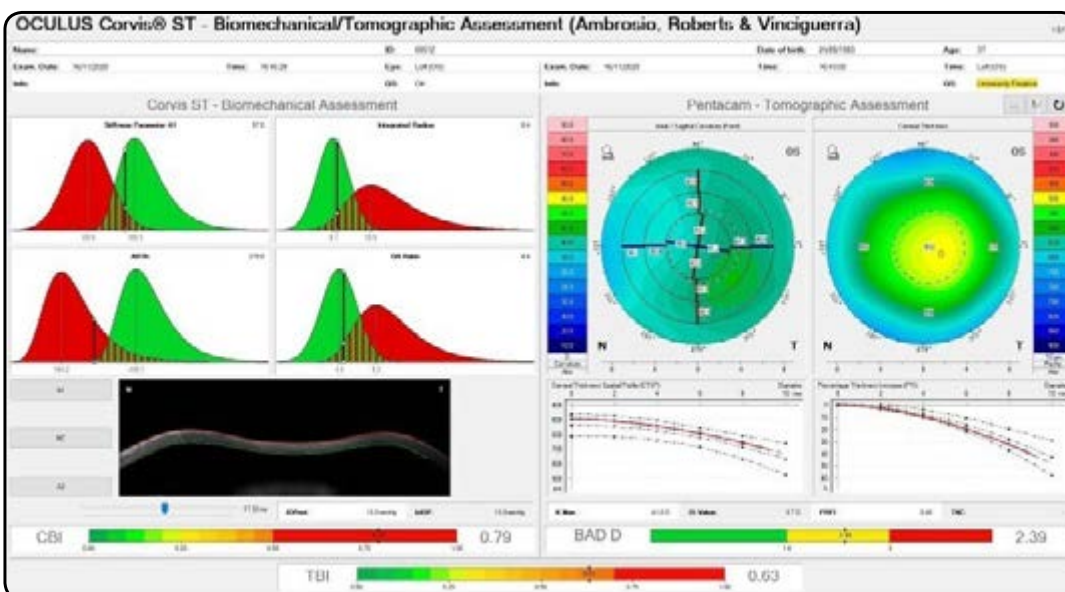
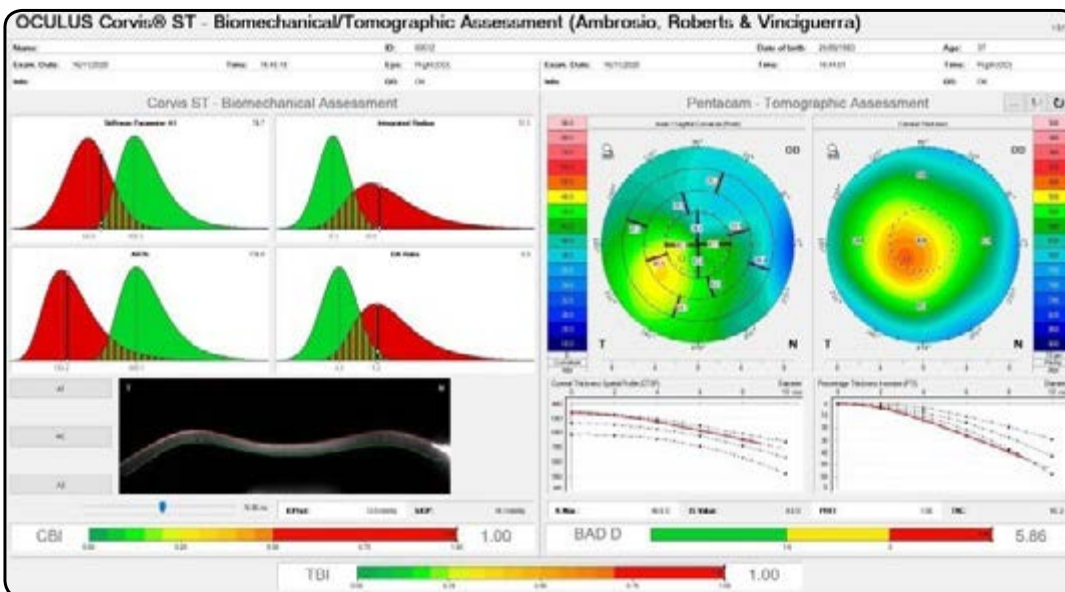


Figure 4 - Corneal tomography integrated system allied with biomechanics. Using Pentacam HR™ and Corvis ST™. BAD, CBI, and TBI altered in OU, revealing asymmetric keratoconus in OD and forme fruste in OS

and 0.79, respectively (Figure 4). They are considered reference values for TBI and CBI, above 0.25 as suspicious and above 0.50 as abnormal. Modular transference function (MTF) showed poor quality of vision in the OD (Figure 5).

Considering the data collected, a diagnosis of keratoconus grade II in the OD and forme fruste in the OS was made. Given the recommendation to stop rubbing his eyes, a follow-up with fewer intervals was suggested to monitor the patient's evolution. Treatment for ocular allergy and nutritional supplements with omega-3 essential fatty acids and oral riboflavin were prescribed. New glasses were prescribed based on the refraction facilitated by the objective examination of the ocular wavefront. The study of low-order aberrations, obtained with the WA-700 and Pentacam AXL-WAVE devices, which use a Hartmann-Shack sensor, made it possible to improve corrected visual acuity. At the given moment, no surgical intervention was indicated.

DISCUSSION

Diagnosis of mild and subclinical keratoconus forms remains a challenge for cornea and refractive surgery specialists. In this context, they constitute an interesting subgroup for diagnostic studies.¹²

As described by the Pan American and Global Consensus on keratoconus, it was established that there is no true unilateral form of keratoconus. However, we know that unilateral ectasias aggravated by mechanical trauma can occur.^{3,5,12,15,22-24}

This report characterizes asymmetric ectasia because it shows the biomechanical susceptibility in the contralateral eye because of a forme fruste keratoconus. The diagnostic advance with corneal tomography combined with biomechanics allowed for identifying subclinical ectasias cases and enabled early propaedeutics, thus avoiding how many patients would have progressed.

The subjective evaluation is effective; however, it is not sufficient. We must understand the perspective of going further, especially in analyzing the anterior surface with corneal topography. With the advent of corneal tomography and tridimensional reconstruction of the corneal architecture, we can characterize the anterior and posterior surface maps, distribution, and

pachymetric pattern; and give us information about the posterior surface preceding the changes in the anterior surface.

In this case, the left eye showed refractive and biomicroscopic data without much emphasizing initial suspicion of the keratoconus condition. The corneal topography revealed low keratometric values and slight astigmatism in the OS (Figures 6 and 7). However, to perform the multimodal evaluation, more data were incorporated to examine and assist in the diagnostic outcome. Despite the patient being of an age in which the disease tends to not progress, the information about the diagnosis instructs us in the ways of preventing aggravation.

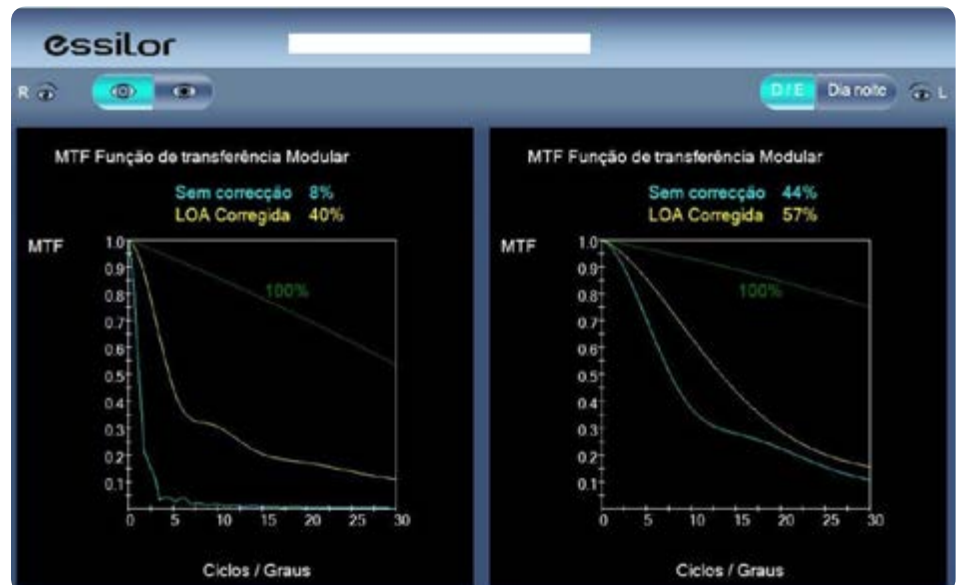
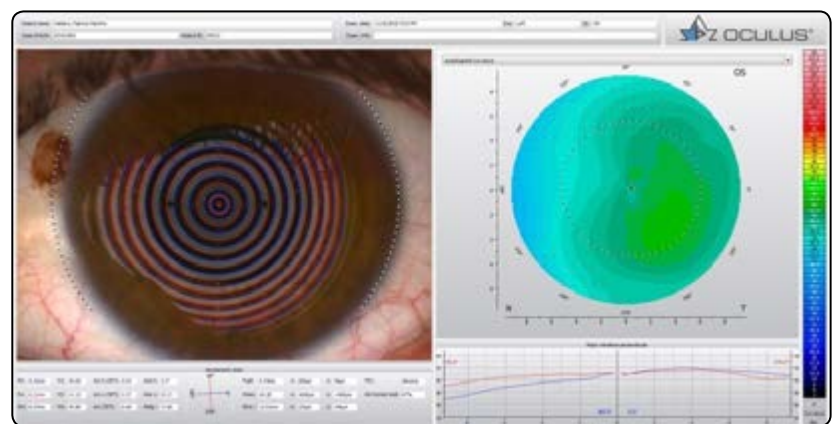
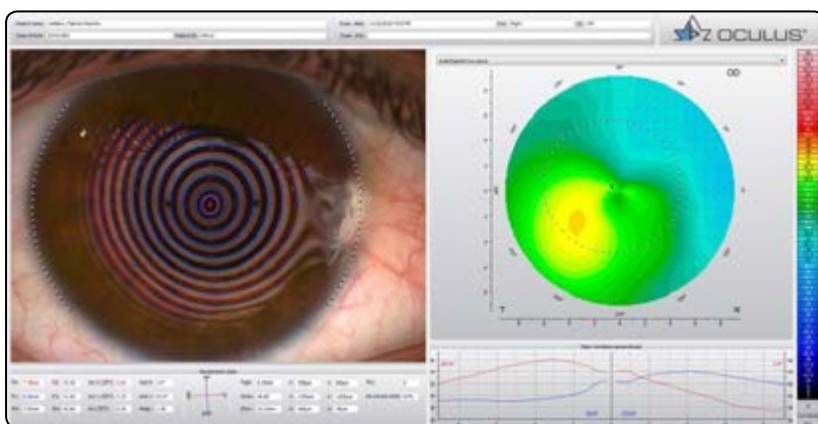


Figure 5 - Modular transfer function (MTF) performed through WAM 700 (Essilor™) reveals the reduced vision quality in the right eye, corroborating with the patient's complaint



Figures 6 e 7 - Anterior axial topography using rotational Scheimpflug, utilizing Keratograph 5

REFERENCES

- Salomão MQ, Hofling-Lima AL, Gomes Esporcatte LP, et. al. The Role of Corneal Biomechanics for the Evaluation of Ectasia Patients. *International journal of environmental research and public health* 2020;17.
- Koh S, Ambrósio R, Jr., Maeda N, Nishida K. Evidence of corneal ectasia susceptibility: a new definition of forme fruste keratoconus. *Journal of cataract and refractive surgery* 2020;46:1570-2.
- Reinstein DZ, Archer TJ, Urs R, Gobbe M, RoyChoudhury A, Silverman RH. Detection of Keratoconus in Clinically and Algorithmically Topographically Normal Fellow Eyes Using Epithelial Thickness Analysis. *Journal of refractive surgery (Thorofare, NJ : 1995)* 2015;31:736-44.
- Gomes JA, Tan D, Rapuano CJ, et. al. Global consensus on keratoconus and ectatic diseases. *Cornea* 2015;34:359-69.
- Fontes BM, Ambrósio R, Jr., Salomão M, Velarde GC, Nosé W. Biomechanical and tomographic analysis of unilateral keratoconus. *Journal of refractive surgery (Thorofare, NJ : 1995)* 2010;26:677-81.
- Ambrósio R, Jr., Belin MW. Imaging of the cornea: topography vs tomography. *Journal of refractive surgery (Thorofare, NJ : 1995)* 2010;26:847-9.
- Kerautret J, Colin J, Touboul D, Roberts C. Biomechanical characteristics of the ectatic cornea. *Journal of cataract and refractive surgery* 2008;34:510-3.
- Li X, Rabinowitz YS, Rasheed K, Yang H. Longitudinal study of the normal eyes in unilateral keratoconus patients. *Ophthalmology* 2004;111:440-6.
- Holland DR, Maeda N, Hannush SB, et. al. Unilateral keratoconus. Incidence and quantitative topographic analysis. *Ophthalmology* 1997;104:1409-13.
- Amsler M. [The "forme fruste" of keratoconus]. *Wiener klinische Wochenschrift* 1961;73:842-3.
- Amsler M. [Classic keratoconus and crude keratoconus; Unitary arguments]. *Ophthalmologica* 1946;111:96-101.
- Gomes JA, Tan D, Rapuano CJ, et. al. Global consensus on keratoconus and ectatic diseases. *Cornea* 2015;34:359-69.
- Esporcatte LPG, Salomão MQ, Lopes BT, et. al. Biomechanical diagnostics of the cornea. *Eye and vision (London, England)* 2020;7:9.
- Eliasy A, Abass A, Lopes BT, et. al. Characterization of cone size and centre in keratoconic corneas. *Journal of the Royal Society, Interface* 2020;17:20200271.
- Ambrósio R, Jr. Violet June: The Global Keratoconus Awareness Campaign. *Ophthalmology and therapy* 2020;9:685-
- Koh S, Ambrósio R, Jr., Inoue R, Maeda N, Miki A, Nishida K. Detection of Subclinical Corneal Ectasia Using Corneal Tomographic and Biomechanical Assessments in a Japanese Population. *Journal of refractive surgery (Thorofare, NJ : 1995)* 2019;35:383-90.
- Ferreira-Mendes J, Lopes BT, Faria-Correia F, Salomão MQ, Rodrigues-Barros S, Ambrósio R, Jr. Enhanced Ectasia Detection Using Corneal Tomography and Biomechanics. *American journal of ophthalmology* 2019;197:7-
- Lopes BT, Ramos IC, Salomão MQ, et. al. Enhanced Tomographic Assessment to Detect Corneal Ectasia Based on Artificial Intelligence. *American journal of ophthalmology* 2018;195:223-32.
- Ambrósio R, Jr., Lopes BT, Faria-Correia F, et. al. Integration of Scheimpflug-Based Corneal Tomography and Biomechanical Assessments for Enhancing Ectasia Detection. *Journal of refractive surgery (Thorofare, NJ : 1995)* 2017;33:434-43.
- Vinciguerra R, Ambrósio R, Jr., Elsheikh A, et. al. Detection of Keratoconus With a New Biomechanical Index. *Journal of refractive surgery (Thorofare, NJ : 1995)* 2016;32:803-10.
- Belin MW, Duncan JK. Keratoconus: The ABCD Grading System. *Klinische Monatsblätter für Augenheilkunde* 2016;233:701-7.
- Ambrósio R, Jr., Lopes B, Faria-Correia F, et. al. Ectasia Detection by the Assessment of Corneal Biomechanics. *Cornea* 2016;35:e18-20.
- Gordon-Shaag A, Millodot M, Shneor E, Liu Y. The genetic and environmental factors for keratoconus. *BioMed research international* 2015;2015:795738.

AUTHOR

SHADY AWWAD

Associate Professor of Ophthalmology and Head of the Department of Cornea and Refractive Surgery at the American University Medical Center in Beirut, Lebanon.



SECTION PUBLISHER

**EMILIO A. TORRES-
NETTO**

Ph.D. candidate at the University of Geneva (Switzerland). Ph.D. candidate at EPM - Unifesp. Specialist in Cornea, Cataract, and Refractive Surgery. Graduated from Stanford University School of Medicine (USA), Irmandade Santa Casa de Misericórdia de São Paulo, Escola Paulista de Medicina - Unifesp, Fondation Ophthalmologique Adolphe de Rothschild (France), ELZA Institute (Switzerland), and University of Zurich (Switzerland).



“The target of customized Excimer Laser ablation in keratoconus is visual rehabilitation: improving corrected distance visual acuity (CDVA) and improving visual symptoms”

EXCIMER LASER SURGERY FOR KERATOCONUS:

When and how?

Customized laser surface treatments in eyes with keratoconus has become possible thanks to the advent of corneal cross-linking. Reviled and revered by surgeons across the globe, it has been the subject of controversy and fierce debates over the past decade. A close, objective review of this procedure identifies its strengths, realistic goals, and limitations, as well as delineates surgical and clinical strategies. The target of customized Excimer Laser ablation in keratoconus is visual rehabilitation: improving corrected distance visual acuity (CDVA) and improving visual symptoms. It is especially useful when rigid gas permeable lenses are not an option, whether it is due to clinical or social intolerance. Customized treatments should not aim at eliminating or minimizing spectacles independence but should rather focus on improving corneal aberrations.

TREATMENT MODALITIES AND PLANNING

In planning for the procedure, the surgeon should keep in mind that the main issues in any customized excimer laser treatment is overcorrection, induction of refractive errors, epithelial and stromal healing, biomechanical adjustment, stromal haze, and especially for keratoconus, biomechanical integrity. There are many reasons for overcorrection, including inputting a refractive correction which has higher order aberrations embedded in it, such as spherical aberration and coma, among others. Hence higher order aberrations and corneal irregularities might be treated twice. Additionally, a larger stromal ablation to offset corneal irregularities entails greater chances to impact the refractive error and can lead to a larger biomechanical adjustment which can also affect the final refractive outcome. Additionally, the

deeper the stromal ablation, the more the chance to develop corneal haze. The latter is not uncommon in irregular eyes, and especially eyes with concomitant or previous procedure like corneal cross-linking.¹⁻⁴ Finally, ablating too deep might affect the biomechanical integrity of the cornea, and reverse any benefit of a previous or concomitant cross-linking procedure. It has been shown that ablating a total of 50 microns was overall safe and did not result in ectasia progression, both simultaneously and sequentially with cross-linking.³ This was further revisited and confirmed 10 years after the procedure.⁵ But this number should be regarded as a maximum to stay away from rather than a safety allowance. The general rule in customized ablations for keratoconus eye should be the less, the better. The target being to fix relevant corneal aberrations rather than refractive errors, the less the stromal ablation, the less the chance to end up with refractive overcorrection, induced refractive errors or aberrations, corneal haze, or ectasia progression. The eye can always be revisited again when more tissue is spared, and the lower order aberrations can be “outsourced” to spectacles, soft contact lenses, or phakic intraocular lenses.

There are many methodologies to perform customized corneal ablation: ocular wavefront-guided (OWG), topography-guided (TG), and PTK treatments. OWG aims at correcting the aberrations of the whole eye, and has an advantage of directly deriving and treating the refractive error from the measured wavefront. However, pupil size often limits the treatment, as the ablation profile has to be extrapolated outside the boundary margins, and a small optical zone treatment in Keratoconus fails to address the irregular corneal changes that typically extend to the mid periphery. The latter concept of a large

optical zone reflects the new trend to treat keratoconus corneal irregularities, and is a sharp departure from the small optical zone initially advocated in the Athens protocol.³ Additio-

nally, traditional aberrometers have low dynamic range and suffer from aliasing when it comes to measuring highly aberrated wavefronts, typically encountered in keratoconus eyes. The

advent of pyramidal aberrometers made it possible to measure complex ocular wavefront patterns, including the ones of eyes with corneal ectasia, and formulate an accurate and reliable

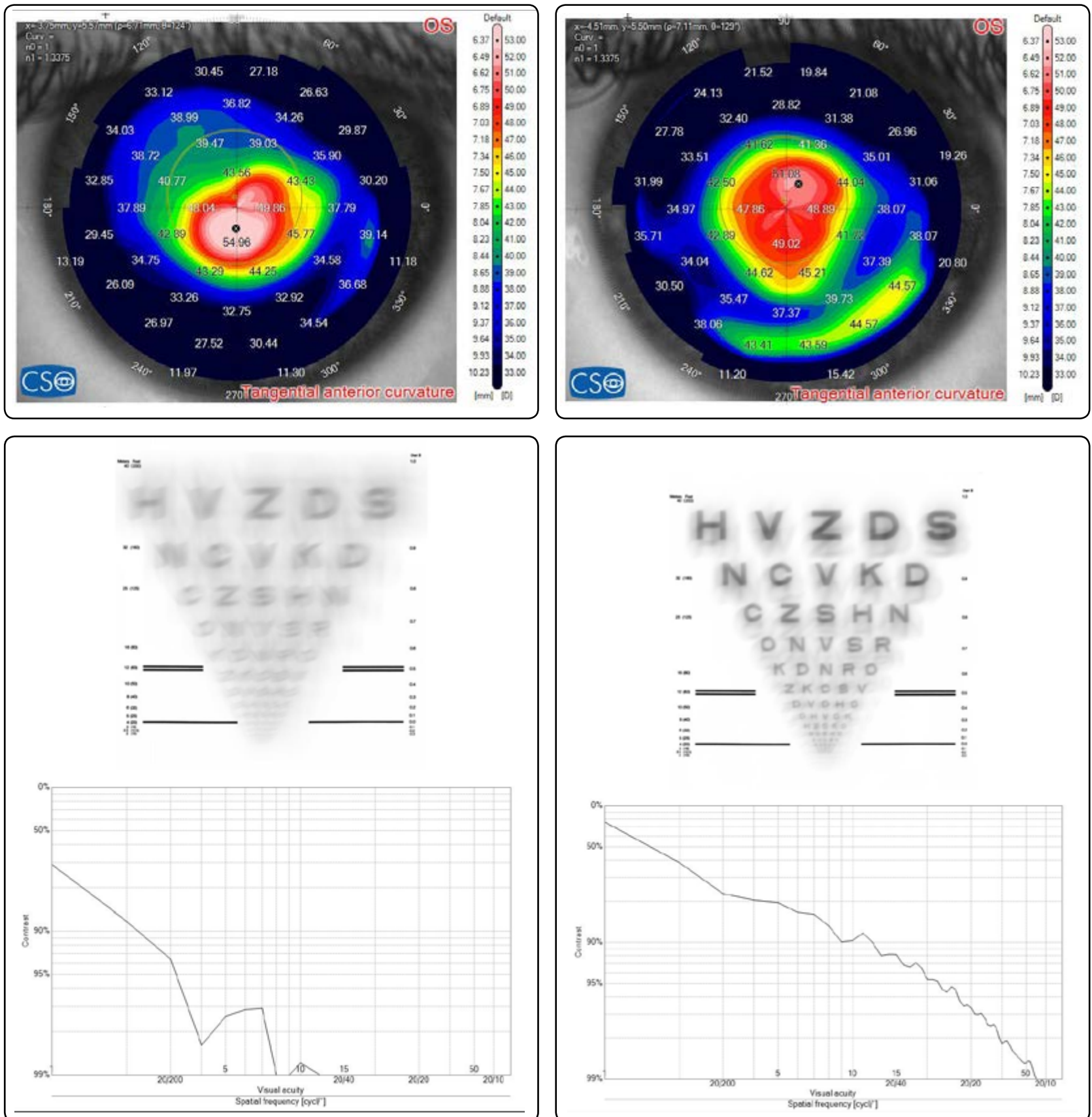


Figure 1 - Preoperative (A) and postoperative (B) tangential curvature topography of an ectatic cornea that underwent combined CXL and large optical zone selective ocular wavefront-guided PRK, using the Peramis pyramidal aberrometer (CSO, Florence, Italy), and the Schwind Amaris excimer laser (Schwind Total Tech Solutions, Kleinostheim, Germany). The main treatment target was higher order aberrations, with minimal stromal tissue ablation. The decentered cone is now less steep and centered on the corneal vertex, with a major improvement in optical quality from preoperative (C) to postoperative (D), with CDVA improving from 20/80 to 20/25.

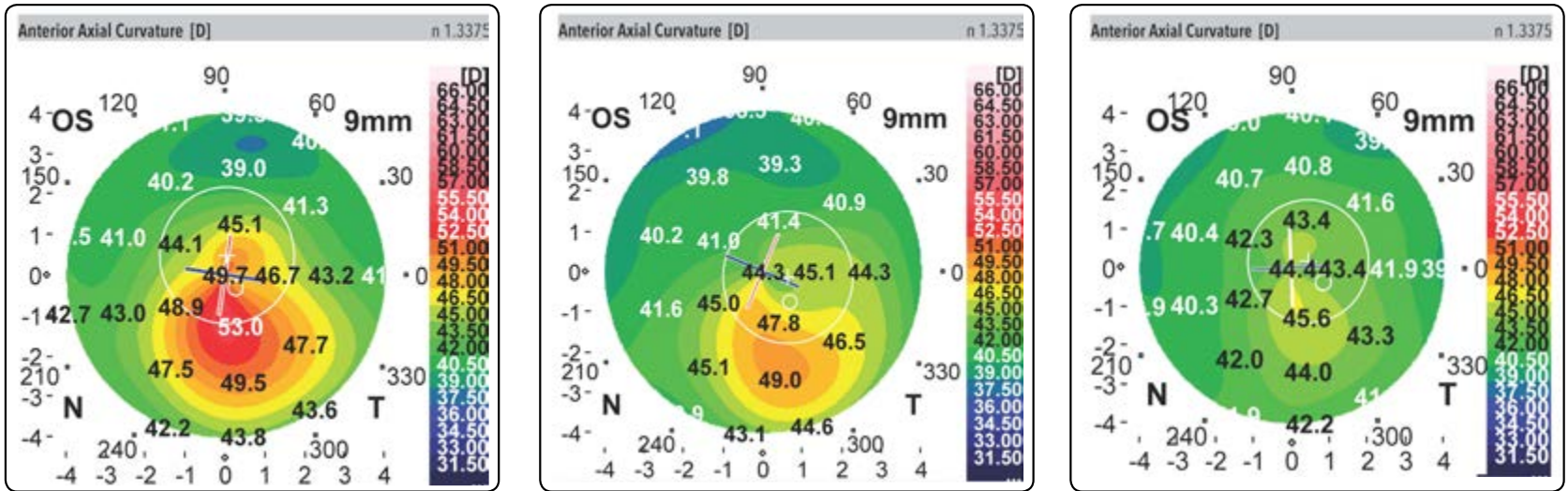


Figure 2 - Preoperative axial curvature corneal topography of a keratoconus eye (A), showing improvement in corneal steepness after undergoing intrastromal corneal ring segment implantation. However, the coma element, represented by inferosuperior asymmetry, remained. The latter was tackled by the more refined combined corneal wavefront-guided PRK with CXL

treatment profiles (**Figure 1**). Topography-guided ablations measure the very surface affected by the disease in a highly predictable and accurate way. Corneal wavefront-guided treatment is a spin-off of the topography-guided method, but rely on decomposition of the topography into wavefront map. By doing so, it provides a way to select and deselect aberrations to be treated, hence allowing for decreased tissue ablation volume and depth while treating the relevant aberrations in a specific eye. Both modalities suffer from the fact that refraction is estimated and never measured directly. More importantly, topography is based on the anterior curvature, which is partially offset by the posterior curvature, sitting on a negative refractive meniscus. Treating the total corneal wavefront (ray-traced sum of anterior and posterior) might provide a better functional treatment and save on tissue ablation. It has already been shown that OWG treatments ablate up to 44% less tissue than CWG ablations, planned on the same eyes using the same excimer platform (Amaris, Schwind Total Tech Solutions, Kleinostheim, Germany).⁷ This difference probably represents the effect of the posterior corneal curvature, which is embedded in OWG treatment profiles. Whether total CWG or OWG treatment more accurately address the corneal aberrations is yet to be determined, as overcorrecting total corneal aberrations by performing an anterior CWG ablation might be offset by an inherent undercorrection of the target aberrations.

Finally, PTK, which is usually reserved to irre-

gularly irregular corneas, can be used in Keratoconus eye to ablate the epithelium, preferentially guided by OCT-derived epithelial maps, and shave some tissues from the cone, where the epithelium is thinnest. This would result in partial treatment of coma, and ensures minimal tissue ablation.⁸⁻¹⁰ This treatment modality would come in handy in severe keratoconus with not much stromal tissue to ablate, or in mild keratoconus with relatively good CDVA where slight acuity boosting with minimal tissue ablation is desired.

SEQUENTIAL VERSUS COMBINED CXL + PRK

Another hot debate in therapeutic refractive surgery for keratoconus is when to perform the customized ablation: in conjunction with CXL or after CXL treatment. Although many surgeons pick sides, it looks like, based on the literature, little evidence is present to fully endorse one over the other, especially that randomized controlled studies are lacking. Instead, clinical experience shows that both can be performed, depending on patient selection and the ultimate goal of the physician in a particular patient. The advantage of combined treatment is that the patient does not have to undergo two procedures, neither would she/he have to wait for a substantial amount of time to ensure stability before undergoing the customized treatment, which is designed to improve the CDVA. Additionally, ablating bowman's layer would improve riboflavin penetration in the cornea, providing deeper cross-linking. Disadvantages of combined treatment are that major changes in corneal

curvature and refraction can develop in some patients, and these are typically unaccounted for by the customized treatments.¹¹ Sequential treatments, on the other hand, have the advantage of treating the cornea after it stabilizes and eliminate major refractive surprises. However, they ablate the very tissue cross-linked, and the stiffest as it is the most anterior. Additionally, patients with subpar CDVA have to wait for at least 6 months and sometimes years to stabilize post CXL in order to undergo a procedure geared to improve their vision. It makes more sense to perform combined treatment in patients suffering from large amounts of higher order aberrations, and poorer CDVA, and as long as the customized ablation is geared to improve HOAs and not LOAs, any major change in corneal flattening post CXL would not negate the initial treatment, and can be taken care of by phakic IOLs, spectacles, and soft contact lenses. On the other hand, eyes with minimal HOAs and relatively good CDVA would benefit from being cross-linked first, and then later undergo customized ablation, if needed. By also doing so, there might be a chance for the patient to improve both in terms of HOAs and LOAs, even if the former was the main target of treatment. It is important to keep in mind that the stromal ablation rate in sequential procedures is less than virgin eyes by about 12%, as has been showed by the group of Hafezi.¹² Hence this should be taken into consideration when planning PRK on previously cross-linked eyes.

HAZE

The development of corneal haze post cross-

-linking has been well documented,^{11,13,14} but it seems that the occurrence is higher when performed with PRK, whether simultaneous or sequential, albeit there is some controversy around which one produces more haze.^{1-3,13,16} Although Kanelopoulos et. al. have reported more haze in the sequential group,³ several studies claim severe haze developing in the simultaneous procedure,^{1,2} which is at odds with other reports claiming minimal to mild haze.^{4-6,8,13,16} The haze sometimes occurs late in onset, in which case it is typically deep^{1,6,17} similar also to what has been reported to occur with cross-linking alone.¹³

A possible reason for the discrepancy in haze between different studies might be the amount of tissue ablated, as this seems to be directly proportional to the amount of haze induced. Another reason is the concomitant use of mitomycin C (MMC). Studies reporting minimal

haze did not use the it at all,^{6,7} or used it for a maximum of 20 seconds,^{3,5,17} while a study reporting severe haze described using mitomycin C for 40 seconds.² We have described marked haze developing after CXL with MMC as opposed to CXL alone, as analyzed by a machine learning algorithm evaluating corneal haze by OCT.¹⁸ It is possible that the combined action of MMC and CXL on the Keratocyte population might be releasing a large surge of cytokines and chemokines which can induce haze.

OUTSOURCING ABERRATIONS TREATMENTS

The motto for the surgeon should be: the less the better. Hence, debulking large aberrations using corneal ring segments (ICRS) or corneal allogenic intrastromal ring segments (CAIRS) would allow for a finer treatment with the Ex-

cimer Laser, achieving less refractive surprises, less haze induction, and better biomechanical integrity,¹⁹⁻²⁰ (Figure 2). In addition, outsourcing the lower order aberrations to phakic IOLs, soft contact lenses, and spectacles would allow most of the ablated tissue to be invested in correcting higher order aberrations and hence, better CDVA.²⁰

CONCLUSION

In conclusion customized laser ablation in Keratoconus is a mainstay in the refractive therapeutic armamentarium of keratoconus management. Proper patient selection and judicious choice of treatment strategy customized the patient's eyes and needs, and targeting higher order aberrations with minimal tissue ablation, in close alliance to other surgical and clinical modalities, are vital to achieve safe and efficacious results.

REFERENCES

- Güell, Jose L, MD, PhD; Verdager, Paula, MD; Elies, Daniel, MD; Gris, Oscar, MD, PhD; Manero, Felicidad, MD. Late Onset of a Persistent, Deep Stromal Scarring After PRK and Corneal Cross-linking in a Patient With Forme Fruste Keratoconus. *J Refract Surg.* Vol. 30, Iss. 4, (Apr 2014): 286-8.
- Moraes RLB, Ghanem RC, Ghanem VC, Santhiago MR. Haze and Visual Acuity Loss After Sequential Photorefractive Keratectomy and Corneal Cross-linking for Keratoconus. *J Refract Surg.* 2019 Feb 1;35(2):109-114. doi: 10.3928/1081597X-20190114-01.
- Kanelopoulos AJ, Vingopoulos F, Sideri AM. Long-Term Stability With the Athens Protocol (Topography-Guided Partial PRK Combined With Cross-Linking) in Pediatric Patients With Keratoconus. *Cornea.* 2019 Aug;38(8):1049-1057.
- Kymionis GD, Portaliou DM, Diakonis VF, Kontadakis GA, Krasia MS, Papadiamantis AG, Coskunseven E, Pallikaris AI. Posterior linear stromal haze formation after simultaneous photorefractive keratectomy followed by corneal collagen cross-linking. *Invest Ophthalmol Vis Sci.* 2010 Oct;51(10):5030-3. doi: 10.1167/iovs.09-5105. Epub 2010 August 18. PMID: 20463316
- Kanelopoulos AJ. Comparison of sequential vs same-day simultaneous collagen cross-linking and topography-guided PRK for treatment of keratoconus. *J Refract Surg.* 2009 Sep;25(9):S812-8. doi: 10.3928/1081597X-20090813-10. Epub 2009 Sep 11. PMID: 19772257
- Georgios A, Kontadakis MD, MSc12Vardhaman, P, Kankariya MD1, Konstantinos Tsoulnaras MD1, Aristofanis I, Pallikaris PhD1, ArgyroPlaka MD, MSc1 <https://www.sciencedirect.com.ezproxy.aub.edu.lb/science/article/pii/S0161642016000555> - Kymionis. Long-Term Comparison of Simultaneous Topography-Guided Photorefractive Keratectomy Followed by Corneal Cross-linking versus Corneal Cross-linking Alone. *Ophthalmology.* Volume 123, Issue 5, May 2016, Pages 974-983
- Daniel M Gore 1, Marcello T Leucci 1, Vijay Anand 1, Luis Fernandez-Vega Cueto 1, Samuel Arba Mosquera 1, Bruce D Allan. Combined wavefront-guided transepithelial photorefractive keratectomy and corneal crosslinking for visual rehabilitation in moderate keratoconus. *J Cataract Refract Surg.* 2018 May;44(5):571-580.
- Kymionis GD, Grentzelos MA, Kounis GA, Diakonis VF, Limnopoulou AN, Panagopoulou SI. Combined transepithelial phototherapeutic keratectomy and corneal collagen cross-linking for progressive keratoconus. *Ophthalmology.* 2012 Sep;119(9):1777-84. doi: 10.1016/j.ophtha.2012.03.038. Epub 2012 Jun 7.
- Grentzelos MA, Liakopoulos DA, Siganos CS, Tsilimbaris MK, Pallikaris IG, Kymionis GD. Long-term Comparison of Combined t-PTK and CXL (Cretan Protocol) Versus CXL With Mechanical Epithelial Debridement for Keratoconus. *J Refract Surg.* 2019 Oct 1;35(10):650-655. doi: 10.3928/1081597X-20190917-01.
- Kymionis GD, Grentzelos MA, Kankariya VP, Liakopoulos DA, Karavitaki AE, Portaliou DM, Tsoulnaras KI, Pallikaris IG. Long-term results of combined transepithelial phototherapeutic keratectomy and corneal collagen crosslinking for keratoconus: Cretan protocol. *J Cataract Refract Surg.* 2014 Sep;40(9):1439-45
- Hafezi F, Koller T, Vinciguerra P, Seiler T. Marked remodelling of the anterior corneal surface following collagen cross-linking with riboflavin and UVA. *Br J Ophthalmol* 2011 Aug;95(8):1171-2.
- Olivier Richoz, Samuel Arba Mosquera, Sabine Kling, Arthur Hammer, Thomas Magnago, Martina M Bosch, Farhad Hafezi. Determination of the excimer laser ablation rate in previously cross-linked corneas. *J Refract Surg.* 2014 Sep;30(9):628-32.
- Ahmad R Dhaini 1, Maamoun Abdul Fattah 2, Sara Maria El-Oud 1, Shady T Awwad. Automated Detection and Classification of Corneal Haze Using Optical Coherence Tomography in Patients With Keratoconus After Cross-Linking. *Cornea* 2018 Jul;37(7):863-869
- Omary R, Shehadeh-Mashor R. Late onset of persistent, deep stromal haze after corneal cross-linking in a patient with keratoconus. *Canadian J Ophthalmol* Volume 52, Issue 2, April 2017, Pages e81-e83
- Tuwairqi WS, Sinjab MM. Safety and efficacy of simultaneous corneal collagen cross-linking with topography-guided PRK in managing low-grade keratoconus: 1-year follow-up. *J Refract Surg.* 2012 May;28(5):341-5. doi: 10.3928/1081597X-20120316-01. Epub 2012 Mar 26. PMID: 22443804
- Hun Lee, David Sung Yong Kang, Byoung Jin Ha, Jin Young Choi, Eung Kweon Kim, Kyoung Yul Seo, Tae-im Kim. Visual rehabilitation in moderate keratoconus: combined corneal wavefront-guided transepithelial photorefractive keratectomy and high-fluence accelerated corneal collagen cross-linking after intracorneal ring segment implantation. *BMC Ophthalmology* volume 17, Article number: 270 (2017)
- Kanelopoulos, Anastasios John MD*,†; Vingopoulos, Filippos MD*; Sideri, Anna Maria MD. Long-Term Stability With the Athens Protocol (Topography-Guided Partial PRK Combined With Cross-Linking) in Pediatric Patients With Keratoconus. *Cornea* August 2019, Volume 38 (8), p 1049-1057
- Awwad ST, Chacra L, Helwe C, Dhaini A., Torbey J, Abdul Fattah M, Telvizian T, Torres-Netto EA, Hafezi F, Shetty R. Mitomycin C Application After Corneal Cross-Linking For Keratoconus Increases Stromal Haze. *J Refract Surg.* 2020 Accepted.
- Waleed Al-Tuwairqi 1, Mazen M Sinjab. Intracorneal ring segments implantation followed by same-day topography-guided PRK and corneal collagen CXL in low to moderate keratoconus. *J Refract Surg.* 2013 Jan; 29(1): 59-63.
- Efehan Coskunseven, Daya Papalkar Sharma, Michael A Grentzelos, Onurcan Sahin, George D Kymionis, Ioannis Pallikaris. Four-Stage Procedure for Keratoconus: ICRS Implantation, Corneal Cross-linking, Toric Phakic Intraocular Lens Implantation, and Topography-Guided Photorefractive Keratectomy. *J Refract Surg.* 2017 Oct 1;33(10):683-689.

BRASCRS

August 18th to 21st

2021

Main attraction: your presence!

The Brazilian Association of Cataract and Refractive Surgery is committed to providing a safe, face-to-face gathering of the subspecialties. For this reason, it has postponed the BRASCRS 2021 congress until the second semester, when the vaccination of the medical community is expected to be completed. The event will be held between August 18th and 21st, at the brand new Salvador Convention Center in Salvador, the capital of Bahia.


With the vaccination of the Ophthalmology community, thousands of colleagues from Brazil and Latin America are expected to show up to learn and teach, but mainly to talk, exchange ideas in the halls, and socialize!

In on the following pages, the activities of the 2021 BRASCRS Congress are described in detail. If you have already registered, take this opportunity to put together your personal program. If you have not yet registered, here is an incentive to run to the site www.brascrs2021.com.br and make your participation a success.

After all, this time it's not about missing an outstanding class, but it is about meeting those professors and long-time friends again in a beautiful, sunny city with that festive atmosphere that everyone certainly misses.

See you there!





CORNEA DAY

August 18th

Grand Auditorium

09:00 - 10:30

CORNEA DAY - CORNEAL BETRAYALS

09:00 - 09:15: Optimizing Treatment of Infectious Keratitis.

09:15 - 09:30: Real and Applicable Advances in Cases of Resistant Ocular Allergies.

09:30 - 09:45: Refining Limbal Stem Cell Transplantation: SSCE and ACER (Sequential Sector Conjunctival Epitheliectomy and Amnion Assisted Conjunctival Epithelial Re-direction).

09:45 - 10:00: Updates in Dry Eye.

10:00 - 10:15: CXL: When, How Much and How

10:15 - 10:30: Discussion.

Grand Auditorium

11:00 - 12:30

CORNEA DAY - CORNEAL FIDELITIES

11:00 - 11:15: Eye Bank for the Corneal Surgeon.

11:15 - 11:30: Scleral Contact Lens in Corneal Diseases.

11:30 - 11:45: DALK.

11:45 - 12:00: Innovations in the Treatment Keratoconus.

12:00 - 12:15: EK.

12:15 - 12:30: DWEK vs. DMEK: Always try DWEK first? Ripasudil?





GLAUCOMA DAY

August 18th

Auditorium 01

09:00 - 10:30

GLAUCOMA DAY

09:00 - 09:10: What is the Importance of IOP in the Monitoring of the Glaucoma Patient?

09:10 - 09:20: Evaluating Functional Loss and Glaucoma Progression in the Patient with Cataracts.

09:20 - 09:30: What are the Most Adequate OCT Parameters in Glaucoma?

09:30 - 09:40: When to Consider SLT.

09:40 - 09:45: Discussion.

09:45 - 09:55: Angular Surgery vs. Fistulizing: How to Choose Between Them.

09:55 - 10:05: Current Evidence of Angular Surgeries.

10:05 - 10:15: XEN e Preserflo: What Do We Know?

10:15 - 10:25: MIGS: Choosing the Right Surgery for the Right Patient.

10:25 - 10:30: Discussion.

Auditorium 01

11:00 - 12:30

GLAUCOMA DAY

11:00 - 11:10: Combined Endothelial Transplantation + Surgical Treatment of Glaucoma: How to Approach it.

11:10 - 11:20: Keratoconus and Its Treatments: Influence on IOP.

11:20 - 11:30: Cataract Surgery in Pseudoexfoliative Glaucoma.

11:30 - 11:40: Cataract and Glaucoma Treatment in the High: What Awaits Us?

11:40 - 11:45: Discussion.

11:45 - 11:55: Which IOL to Choose in Glaucoma Patients.

11:55 - 12:05: Cataract and Glaucoma in Uveitis: Reviewing Surgical Options.

12:05 - 12:15: Differences between Cataract Approach in GPAF and GPAA.

12:15 - 12:25: Glaucoma and Dry Eye: How do you Approach it?

12:25 - 12:30: Discussion.

FREE THEORETICAL COURSES



Mezzanine 01

Day 08/18 | 14:00 - 15:30

ESSENTIAL PHACO – EQUIPMENT, FLUIDICS, TECHNIQUES, AND STEP-BY-STEP

Mezzanine 03

Day 08/18 | 14:00 - 15:30

COMPLEMENTARY CORNEA AND ANTERIOR SEGMENT EXAMS: TECHNOLOGICAL NEWS

Mezzanine 04

Day 08/18 | 14:00 - 15:30

JUNIOR BRASCRS

Mezzanine 06

Day 08/18 | 14:00 - 15:30

ZONULAR FRAGILITY & SUBLUXATION – THEORY AND PRACTICE, WITH VIDEOS AND CASE DISCUSSIONS

Mezzanine 07

Day 08/18 | 14:00 - 15:30

PTERYGIUM – TREATMENT AND COMPLICATION MANAGEMENT

Mezzanine 08

Day 08/18 | 14:00 - 15:30

ESSENTIALS IN TOPOGRAPHY & TOMOGRAPHY

Mezzanine 09

Day 08/18 | 14:00 - 15:30

INTRAOCULAR LENS CALCULATION IN 2021

Mezzanine 01

Day 08/18 | 16:00 - 18:00

PHACO TECHNIQUES

Mezzanine 03

Day 08/18 | 16:00 - 18:00

PRESBYOPIA

Mezzanine 04

Day 08/18 | 16:00 - 18:00

BRASCRS INNOVATIONS

Mezzanine 06

Day 08/18 | 16:00 - 18:00

PHAKIC IOLs

Mezzanine 07

Day 08/18 | 16:00 - 18:00

INFECTIOUS ENDOPHTHALMITIS: EVERYTHING THAT YOU NEED TO KNOW

Mezzanine 08

Day 08/18 | 16:00 - 18:00

HOW TO PRAISE COMPLEMENTARY ANTERIOR SEGMENT EXAMS

Mezzanine 09

Day 08/18 | 16:00 - 18:00

BRAZILIANS AROUND THE WORLD

Mezzanine 01

Day 08/18 | 09:00 - 10:30

REFRACTIVE COMPLICATIONS: CASES AND VIDEOS

Mezzanine 03

Day 08/18 | 09:00 - 10:30

CAPSULAR RUPTURE – EVERYTHING ABOUT IT

Mezzanine 06

Day 08/18 | 09:00 - 10:30

PHACO 3D – THEORY AND PRACTICE WITH VIDEOS AND CASE DISCUSSIONS

Mezzanine 09

Day 08/18 | 09:00 - 10:30

RING

Mezzanine 01

Day 08/18 | 11:00 - 12:30

COMBINED SURGERIES – THEORY AND PRACTICE

Mezzanine 03

Day 08/18 | 11:00 - 12:30

LASIK

Mezzanine 06

Day 08/18 | 11:00 - 12:30

ADVANCED BIOMETRY

Mezzanine 09

Day 08/18 | 11:00 - 12:30

HIGH PERFORMANCE

Mezzanine 01

Day 08/18 | 14:00 - 15:30

GLAUCOMA FOR THE ANTERIOR SEGMENT SURGEON: CLINICAL TREATMENT AND SURGICAL OPTIONS

Mezzanine 03

Day 08/18 | 14:00 - 15:30

CORNEAL LENTICULE EXTRACTION WITH REFRACTIVE FINALITY: EVERYTHING ABOUT IT

Mezzanine 06

Day 08/18 | 14:00 - 15:30

CROSSLINKING

Mezzanine 09

Day 08/18 | 14:00 - 15:30

HUMANITARIAN OPHTHALMOLOGY

Auditorium 01

Day 08/20 | 09:00 - 10:30

REFRACTIVE SYMPOSIUM 06 – ISRS



Mezzanine 01

Day 08/20 | 09:00 - 10:30

INTRAOCULAR DEVICES (EXPANDERS, RINGERS, RETRACTORS, MIGS, AND PROSTHESES)

Mezzanine 03

Day 08/20 | 09:00 - 10:30

BIOMETRY: EQUIPMENT AND FORMULAS

Mezzanine 09

Day 08/20 | 09:00 - 10:30

WILL YOU FACE IT?

Auditorium 01

Day 08/20 | 11:00 - 12:30

REFRACTIVE SYMPOSIUM – COMPLEMENTARY EXAMS AND NEW TECHNOLOGIES

Mezzanine 01

Day 08/20 | 11:00 - 12:30

IOL FIXATION & SECONDARY IMPLANTATIONS - THEORY AND PRACTICE WITH VIDEOS AND CASE DISCUSSIONS

Mezzanine 03

Day 08/20 | 11:00 - 12:30

BIOMETRY: DISCUSSION OF CLINICAL CASES

Mezzanine 06

Day 08/20 | 11:00 - 12:30

CATARACT COMPLICATIONS: CASES AND VIDEOS

Mezzanine 09

Day 08/20 | 11:00 - 12:30

SCIENTIFIC METHODOLOGY

Mezzanine 01

Day 08/20 | 14:00 - 15:30

EXCIMER LASER IN THERAPEUTIC SURGERIES (PTK, TOPO-GUIDED, ETC.)

Mezzanine 04

Day 08/20 | 14:00 - 15:30

ECTASIA POST-REFRACTIVE SURGERY: DAYGNOSIS, THERAPIES, OUTCOMES, AND COMPLICATIONS

Mezzanine 06

Day 08/20 | 14:00 - 15:30

ANTERIOR LAMELLAR CORNEAL TRANSPLANTATIONS

Mezzanine 07

Day 08/20 | 14:00 - 15:30

PEDAYTRIC CATARACT

Mezzanine 08

Day 08/20 | 14:00 - 15:30

RETINA FOR THE ANTERIOR SEGMENT SURGEON - UPDATE ON THE MOST PERTINENT THEMES

Auditorium 01

Day 08/20 | 16:00 - 18:00

REFRACTIVE SYMPOSIUM – INSTRUCTIVE CASES, CHALLENGES, AND COMPLICATIONS

Mezzanine 01

Day 08/20 | 16:00 - 18:00

ADVANCED PROPEDEUTICS REFRACTIVE SURGERY (TOMOGRAPHY, BIOMECHANICS, ABERROMETRY)

Mezzanine 03

Day 08/20 | 16:00 - 18:00

TORIC IOLs

Mezzanine 06

Day 08/20 | 16:00 - 18:00

POSTERIOR ENDOTHELIAL / LAMELLAR CORNEAL TRANSPLANTATIONS

Mezzanine 07

Day 08/20 | 16:00 - 18:00

RESIDUAL AMETROPIA IN PSEUDOPHAKIC PATIENTS: PROGRAMMING THE “FINE TUNING”

Mezzanine 02

Day 08/21 | 09:00 - 10:30

BRAZILIAN ASSOCIATION OF OPHTHALMOLOGY ACADEMIC LEAGUES

Mezzanine 03

Day 08/21 | 09:00 - 10:30

TRIOFOCAL IOLs, EDOF, & NEW TECHNOLOGIES

Mezzanine 06

Day 08/21 | 09:00 - 10:30

ADVANCED KERATOCONUS

Mezzanine 07

Day 08/21 | 09:00 - 10:30

EVERYDAY CASES IN REFRACTIVE SURGERY: CHOICE OF TECHNIQUE – CASES / VIDEOS

Mezzanine 09

Day 08/21 | 09:00 - 10:30

PRK, PTK & SURFACE ABLATIONS

Mezzanine 02

Day 08/21 | 11:00 - 12:30

ESCRS (Virtual Session)

Mezzanine 03

Day 08/21 | 11:00 - 12:30

FEMTO PHACO – THEORY AND PRACTICE WITH VIDEOS AND CASE DISCUSSIONS

Mezzanine 06

Day 08/21 | 11:00 - 12:30

COMPLEX CATARACT CASES: CASE DISCUSSION/ VIDEOS

Mezzanine 07

Day 08/21 | 11:00 - 12:30

NEW TREATMENT MODALITIES FOR MGD & DRY EYE

Mezzanine 09

Day 08/21 | 11:00 - 12:30

EXCIMER LASER: DE-MYSTIFYING TOPO-GUIDED & CUSTOMIZED SURGERIES THROUGH ABERROMETRY

GAC - THE GRAND ARCHIVE OF CASES

August 18th to 20th

Mezzanine 02

Day 08/18 | 14:00 - 15:30

THE GRAND ARCHIVE OF CASES - CLINICAL CASE PRESENTATIONS

Mezzanine 05

Day 08/18 | 14:00 - 15:30

THE GRAND ARCHIVE OF CASES - CLINICAL CASE PRESENTATIONS

Mezzanine 02

Day 08/18 | 16:00 - 18:00

THE GRAND ARCHIVE OF CASES - CLINICAL CASE PRESENTATIONS

Mezzanine 05

Day 08/18 | 16:00 - 18:00

THE GRAND ARCHIVE OF CASES - CLINICAL CASE PRESENTATIONS

Mezzanine 02

Day 08/18 | 09:00 - 10:30

THE GRAND ARCHIVE OF CASES - CLINICAL CASE PRESENTATIONS

Mezzanine 05

Day 08/18 | 09:00 - 10:30

THE GRAND ARCHIVE OF CASES - CLINICAL CASE PRESENTATIONS

Mezzanine 02

Day 08/18 | 11:00 - 12:30

THE GRAND ARCHIVE OF CASES - CLINICAL CASE PRESENTATIONS

Mezzanine 05

Day 08/18 | 11:00 - 12:30

THE GRAND ARCHIVE OF CASES - CLINICAL CASE PRESENTATIONS

Mezzanine 02

Day 08/18 | 14:00 - 15:30

THE GRAND ARCHIVE OF CASES - CLINICAL CASE PRESENTATIONS

Mezzanine 05

Day 08/18 | 14:00 - 15:30

THE GRAND ARCHIVE OF CASES - CLINICAL CASE PRESENTATIONS

Mezzanine 02

Day 08/20 | 09:00 - 10:30

THE GRAND ARCHIVE OF CASES - CLINICAL CASE PRESENTATIONS

Mezzanine 05

Day 08/20 | 09:00 - 10:30

THE GRAND ARCHIVE OF CASES - CLINICAL CASE PRESENTATIONS

Mezzanine 02

Day 08/20 | 11:00 - 12:30

THE GRAND ARCHIVE OF CASES - CLINICAL CASE PRESENTATIONS

Mezzanine 05

Day 08/20 | 11:00 - 12:30

THE GRAND ARCHIVE OF CASES - CLINICAL CASE PRESENTATIONS

SYMPOSIUMS

August 18th to 21st

Auditorium 01

Day 08/18 | 14:00 - 15:30

REFRACTIVE SYMPOSIUM – KERATOCONUS AND CORNEAL ECTASIAS

14:00 - 14:12: Critical Analysis of the Diagnostic Methods for Keratoconus

14:12 - 14:24: Use of the Epithelial Map in the Diagnosis and Monitoring of Keratoconus.

14:24 - 14:36: Innovations in Keratoconus.

14:36 - 14:48: Crosslinking: Indications and Techniques.

14:48 - 15:00: Crosslinking: Long-Term Follow-up.

15:00 - 15:12: Crosslinking: Complications, Re-treatment, and Failures.

15:12 - 15:30: Discussion.

Grand Auditorium

Day 08/18 | 14:00 - 15:30

CATARACT SYMPOSIUM – PREMIUM IOLs

14:00 - 14:12: Multifocal Lenses: I've been through them all and I am here.

14:12 - 14:24: Symphony Implant in Special Cases (Glaucoma, Posterior Polar Cataract, and Trauma).

14:24 - 14:36: Vivivity, First Results.

14:36 - 14:48: Presbyopia Correction with SulcoFlex Trifocal.

14:48 - 15:00: Refractive and Visual Outcomes with PanOptix Diffractive Trifocal in a Large Population.

15:00 - 15:12: Critical Analysis and Clinical Outcomes of Different Technologies.

15:12 - 15:30: Discussion.

Auditorium 01

Day 08/18 | 16:00 - 18:00

REFRACTIVE SYMPOSIUM – KERATOCONUS AND CORNEAL ECTASIAS

16:00 - 16:12: Topographic and Aberrometric Pattern Analysis in the Choice of the Correct Intraocular Ring.

16:12 - 16:24: Keratoconus: Treatment with Asymmetric Segments and Hybrid Technique.

16:24 - 16:36: The ring prevents the progression of keratoconus?

16:36 - 16:48: Refractive Treatment of Keratoconus.

16:48 - 17:00: Simultaneous PRK and CXL.

17:00 - 17:12: Corneal Remodeling: a new technique for keratoconus.

17:12 - 17:24: Intraocular Lens Implantation in Keratoconus: Phakic, Pseudophakic, and Special (Pinhole).

17:24 - 17:36: The Cross Linking Role in Refractive Surgery.

17:36 - 17:48: New Intraocular Ring Models.

17:48 - 18:00: Discussion.

Grand Auditorium

Day 08/18 | 16:00 - 18:00

CATARACT SYMPOSIUM – WHAT'S NEW IN IOLs

16:00 - 16:12: Improve your Refractive Outcomes in Trifocals IOLs With Technology and Systems.

16:12 - 16:24: Intraocular Lenses for Macular Degeneration.

16:24 - 16:36: New IOL Features for PCO Prevention.

16:36 - 16:48: Hybrid Technology Intraocular Lenses for Presbyopic Correction.

16:48 - 17:00: Presbyopic IOL Correction Following LASIK.

17:00 - 17:12: Intraocular Lenses in Aberrated Corneas.

17:12 - 17:24: Small Aperture IOLs for Aberrated Corneas.

17:24 - 17:36: Algorithm for Intraocular Lens Selection.

17:36 - 17:48: New "Intensity" Lens (Pentafocal).

17:48 - 18:00: Discussion.

Auditorium 01

Day 08/18 | 09:00 - 10:30

REFRACTIVE SYMPOSIUM - HOTTEST IN REFRACTIVE SURGERY

09:00 - 09:12: Nanotechnology in the Cornea and Lens for Vision Correction.

09:12 - 09:24: Finite Element Modeling for Decision Making in Laser Vision Correction.

09:24 - 09:36: Ocular Biomechanics: Measurement Techniques and Clinical Value in Ophthalmology.

09:36 - 09:48: Case Studies of a Novel Method to Assist With T-CAT Treatments for Irregular Corneas.

09:48 - 10:00: Longterm Denervation After SMILE and LASIK.

10:00 - 10:12: Quality of Vision Beyond 20/20.

10:12 - 10:30: Discussion.

Grand Auditorium

Day 08/18 | 09:00 - 10:30

CATARACT SYMPOSIUM - EXCELLENCE IN BIOMETRY: OBSESSION WITH RESULTS

09:00 - 09:12: BRASCRS calculator.

09:12 - 09:24: IOL 2021 Calculation Update.

09:24 - 09:36: Biometry in Extreme Ametropias.

09:36 - 09:48: Measuring The Cornea: Are We Doing Better?

10:00 - 10:12: Refractive Excellence in Cataract Surgery.

Lecturer: Arnaldo Espaillat Matos - Dominican Republic

10:12 - 10:30: Discussion.

Auditorium 01

Day 08/18 | 11:00 - 12:30

REFRACTIVE SYMPOSIUM – INTRAOCULAR REFRACTIVE SURGERY

11:00 - 11:12: Decision Making in Corneal and Lens Based Refractive Surgery: A Case Based Approach.

11:12 - 11:24: ICL or Lasik?

11:24 - 11:36: More than 5 years of experience with Implantation of Iris Fixation and Posterior Chamber Phakic Lenses for Different Degrees of Myopia.

11:36 - 11:48: Posterior Chamber Implantations for High Myopia ICL, Patient Evaluation in 10 years.

11:48 - 12:00: How to Study My Patient with Keratoconus for the Phakic Lens Surgery.

12:00 - 12:12: Multifocal IOLs. Extensive Experience with Synergy, Eyhance, Vivity, & Liberty.

12:12 - 12:30: Discussion.

Grand Auditorium

Day 08/18 | 11:00 - 12:30

CATARACT SYMPOSIUM – PHACO NIGHTMARES

11:00 - 11:12: Retropulsion Syndrome of the Irido-Crystalline Dayphragm.

11:12 - 11:24: Posterior Capsule Rupture.

11:24 - 11:36: Severe Scleromalacia and Cataract.

11:36 - 11:48: Small Pupil.

11:48 - 12:00: Transoperative Accidents. Your Solution.

12:00 - 12:12: Phaco Nightmares.

12:12 - 12:30: Discussion.

Auditorium 01

Day 08/18 | 14:00 - 15:30

REFRACTIVE SYMPOSIUM - REFRACTIVE TREATMENTS WITH EXCIMER LASER

14:00 - 14:12: Lasikonomics 2021: Numbers Around Refractive Surgery post-Pandemia.

14:12 - 14:24: PRK in Ametropias post-Phaco.

14:24 - 14:36: The Quest for Super-Vision: Topography Guided Surgery and Beyond.

14:36 - 14:48: PTK + PRK versus STREAMLIGHT.

14:48 - 15:00: Management of the Subluxated Flap.

15:00 - 15:12: Femtolasik in Post-Phakci Ametropias.

15:12 - 15:30: Discussion.

Grand Auditorium

Day 08/18 | 14:00 - 15:30

CATARACT SYMPOSIUM - HOTTEST IN CATARACT

14:00 - 14:12: From Great to Unstoppable in Cataract Surgery.

14:12 - 14:24: Refractive Index Shape Changing of IOLs.

14:24 - 14:36: Intra-Operative Aberrometry.

14:36 - 14:48: A new EDOF concept based on shifting and stratching the wavefront: 18 months experience.

14:48 - 15:00: Update On Accommodating IOLs.

15:00 - 15:12: The Role Machine Learning of Lens Thickness and it Effect on IOL Power Calculation.

15:12 - 15:30: Discussion.

Grand Auditorium

Day 08/20 | 09:00 - 10:30

CATARACT SYMPOSIUM – NEW TECHNOLOGIES

09:12 - 09:24: New Technologies in Cataract Surgery.

09:24 - 09:36: Cataract Surgery in 3D.

09:36 - 09:48: Intra-chamber Antibiotics.

09:48 - 10:00: Dropleess Cataract Surgery.

10:00 - 10:12: Intraoperative Wave Front: The Great Advance for Cataract Surgery.

10:12 - 10:30: Discussion.

Grand Auditorium

Day 08/20 | 11:00 - 12:30

ARGENTINA SYMPOSIUM (SACRYC)

Grand Auditorium

Day 08/20 | 14:00 - 15:30

CATARACT SYMPOSIUM - INSTRUCTIVE CASES, CHALLENGES, & COMPLICATIONS

14:00 - 14:12: Case 1.

14:12 - 14:24: Traumatic Cataract: Surgical Pearls.

14:24 - 14:36: Exchange of a "Perfect" IOL.

14:36 - 14:48: Dislocated IOL Management: An Algorithm.

14:48 - 15:00: Case 2.

15:00 - 15:12: Intumescent Cataract Management.

15:12 - 15:30: Discussion.

Grand Auditorium

Day 08/20 | 16:00 - 18:00

CATARACT SYMPOSIUM – INSTRUCTIVE CASES, CHALLENGES, & COMPLICATIONS

Discussants: Newton Leitão de Andrade - CE / Alexandre Hasler Principe de Oliveira - BA

16:00 - 16:12: Subluxated Crystalline Lens Surgical Treatment.

16:12 - 16:24: Cataract Surgery Considerations in Patients With Phakic IOLs.

16:24 - 16:36: Rescued IOLs (Managing Complex Cataract Cases).

16:36 - 16:48: Pitfalls in Dealing With Uveitic Cataract.

16:48 - 17:00: Discussion.

17:00 - 17:12: Combating Aphakia.

17:12 - 17:24: Mature Cataract Surgery with the Ultrachopper.

17:24 - 17:36: 20 Forms of Posterior Capsule Rupture.

17:36 - 17:48: What is New on White Cataract Management.

17:48 - 18:00 Discussion.

Auditorium 01

Day 08/21 | 09:00 - 10:30

REFRACTIVE SYMPOSIUM – PRESBYOPIA TREATMENT

09:00 - 09:12: Presbyopia Treatment in the Cornea or in the Crystalline Lens? Selection Criteria.

09:12 - 09:24: Expanding the Depth of Focus.

09:24 - 09:36: Add-on IOLs for Presbyopia or Refractive Error Correction Post-Phaco.

09:36 - 09:48: LIRIC (Laser Induce Refractive Index Change) for the treatment of Presbyopia.

09:48 - 10:00: Evolution in Presbylasik.

10:00 - 10:12: Tissue Response Following Scleral Microporation for Prebyopia Therapy.

10:12 - 10:30: Discussion.

Grand Auditorium

Day 08/21 | 09:00 - 10:30

CATARACT SYMPOSIUM - EXTRA CAPSULAR CATARACT FACPECTOMY

09:00 - 09:12: Why Does The Modern Cataract Surgeon Need To Know the Extracapsular Facpectomy?

09:12 - 09:24: When and How one Should Perform Phaco Conversion to ECF.

09:24 - 09:36: Contemporary Approach of MSICS for extracapsular lens extraction.

09:36 - 09:48: PHACO-SIMILE and Other Manual Fracture Techniques.

09:48 - 10:00: Incision Types and Sites in Manual Cataract Surgeries.

10:00 - 10:12: Refraction Management.

10:12 - 10:30: Discussion.

Mezzanine 01

Day 08/21 | 09:00 - 10:30

RETINA SYMPOSIUM 01

09:00 - 09:10: OCT in Preoperative Cataract.

09:10 - 09:20: Perioperative Care of the High Myope.

09:20 - 09:30: Multifocal Lenses in Patients with Macular Diseases.

09:30 - 09:45: Discussion

09:45 - 09:55: Floaters and Cataract Surgery.

09:55 - 10:05: Cystoid Macular Edema – Daygnosis and Treatment.

10:05 - 10:15: Cataract in the Vitrectomized Eye.

10:15 - 10:30: Discussion

Auditorium 01

Day 08/21 | 11:00 - 12:30

REFRACTIVE SYMPOSIUM - PRESBYOPIA TREATMENT

11:00 - 11:12: Pharmacological Management of Presbyopia.

11:12 - 11:24: Presbyopic Surgery. Monovision with Plus Monofocals vs. Trifocal IOLs.

11:24 - 11:36: Trifocal IOLs in Brazill: My Experience with Synergy, Panoptix e Zeiss.

11:36 - 11:48: Multifocal Piggyback, An Alternative.

11:48 - 12:00: Management of Presbyopia with Prior Refractive Surgery.

12:00 - 12:12: Management of the Dissatisfied Patient after Multifocal Lens Implantation.

12:12 - 12:30: Discussion

Grand Auditorium

Day 08/21 | 11:00 - 12:30

CATARACT SYMPOSIUM - DISSATISFIED PATIENTS: CAUSES AND SOLUTIONS

11:00 - 11:12: Floaters.

11:12 - 11:24: Dysphotopsias after Cataract Surgery.

11:24 - 11:36: Low Vision Without Apparent Cause.

11:36 - 11:48: Decentered / Dislocated IOL.

11:48 - 12:00: Corneal Edema.

12:00 - 12:12: Residual Ametropia.

12:12 - 12:30: Discussion.

Mezzanine 01

Day 08/21 | 11:00 - 12:30

RETINA SYMPOSIUM 01

11:00 - 11:10: Daybetic Retinopathy and Cataract.

11:10 - 11:20: Cataract Surgery in Patients with Retinal Dystrophy.

11:20 - 11:30: Retinal Detachment in Pseudophakia.

11:30 - 11:45: Discussion.

11:45 - 11:55: Posterior Segment Complications During Cataract Surgery.

11:55 - 12:05: TASS vs. Endophthalmitis: Current Approach.

12:05 - 12:15: Phaco-Vitrectomy Combined Surgery: Indications and Techniques.

12:15 - 12:30: Discussion.

BUSINESS MORNING

August 18th

Exhibition

09:00 - 10:30

Business Morning

Exhibition

11:00 - 12:30

Business Morning

PHACOMANIA

August 18th

Grand Auditorium

18:30 - 19:30





FILM FESTIVAL

August 19th

Grand Auditorium
18:30 - 19:30

FREE THEME

August 20th

Mezzanine 02
14:00 - 15:30

FREE THEME 01

Mezzanine 09
14:00 - 15:30

FREE THEME 03

Mezzanine 09
16:00 - 18:00

FREE THEME 02

WET LABS

Activity	Date	Time
DL 01 - Laser in Glaucoma	08/18/21	16:00 to 17:30
WL 01 - IOLs Scleral Fixation (Yamane Technique) - Group 1	08/18/21	16:00 to 17:30
WL 02 - Anterior Vitrectomy in Cataract Surgery - Group 1	08/18/21	16:00 to 17:30
WL 03 - Pterygium - Conjunctiva Transplantation with Biological Glue - Group 1	08/18/21	16:00 to 17:30
WL 04 - Praticum in Toric IOL Marking and Implantation - Group 1	08/18/21	16:00 to 17:30
WL 05 - How to Train Cataract Surgery at Home (Exclusively for Residents)	08/18/21	16:00 to 17:30
DL 02 - Advanced Corneal Tomography	08/19/21	09:00 to 10:30
WL 06 - New Scleral Fixation Technique - 4 Flanged Technique - Group 1	08/19/21	09:00 to 10:30
WL 07 - Phacoemulsification - Theory and Practice	08/19/21	09:00 to 10:30
WL 08 - MIGS (Microinvasive Glaucoma Surgery) - Group 1	08/19/21	09:00 to 10:30
WL 09 - Iris Suture and Intraocular Lens Fixation - Group 1	08/19/21	09:00 to 10:30
WL 32 - Eyelab preparation for phaco A to Z	08/19/21	09:00 to 10:30
DL 03 - Safety Calculation for Refractive Surgeries	08/19/21	11:00 to 12:30
DL 04 - Crosslinking	08/19/21	11:00 to 12:30
WL 10 - IOLs Scleral Fixation (Yamane Technique) - Group 2	08/19/21	11:00 to 12:30
WL 11 - Anterior Vitrectomy in Cataract Surgery - Group 2	08/19/21	11:00 to 12:30
WL 12 - Pterygium - Conjunctiva Transplantation with Biological Glue - Group 2	08/19/21	11:00 to 12:30
WL 13 - Capsulorhexis (Theory + Practice - Wet Lab with Kitaro)	08/19/21	11:00 to 12:30
DL 05 - Pentacam in Cataract	08/19/21	14:00 to 15:30
DL 06 - Pentacam Interpretation	08/19/21	14:00 to 15:30
WL 14 - Iris Expander Ring - Canabrava Ring - Group 1	08/19/21	14:00 to 15:30
WL 15 - Ferrara Ring and Nomogram - Manual Technique and with Femtosecond Laser	08/19/21	14:00 to 15:30
WL 16 - MIGS (Microinvasive Glaucoma Surgery) - Group 2	08/19/21	14:00 to 15:30
WL 17 - Practice in Toric IOL Marking and Implantation - Group 2	08/19/21	14:00 to 15:30
DL 07 - Scleral Lenses Theory / Practice	08/20/21	09:00 to 10:30
WL 18 - New Scleral Fixation Technique - 4 Flanged Tehcnique - Group 2	08/20/21	09:00 to 10:30
WL 19 - Pre-Slice (Wet Lab with Kitaro)	08/20/21	09:00 to 10:30
WL 20 - Keraring (Ring and Nomogram)	08/20/21	09:00 to 10:30
WL 21 / WL 25 - DMEK (Descemet Membrane Endothelial Keratoplasty), PDEK (Pre Descemet Membrane Endothelial Keratoplasty), DWEK (Descemetorhexis without Endothelial Keratoplasty)	08/20/21	09:00 to 10:30 11:00 to 12:30
DL 08 - Galilei from basic to advanced in Refractive and Cataract	08/20/21	11:00 to 12:30
WL 22 - IOLs Scleral Fixation (Yamane Technique) - Group 3	08/20/21	11:00 to 12:30
WL 23 - Artisan / Artiflex Phakic IOLs with Silicone Artificial Eye	08/20/21	11:00 to 12:30
WL 24 - Multifocal IOL Practice: Care, Assembly, and Implantation	08/20/21	11:00 to 12:30
WL 27 - Anterior Vitrectomy in Cataract Surgery - Group 3	08/20/21	14:00 to 15:30
WL 28 - Iris Suture and Intraocular Lens Fixation - Group 2	08/20/21	14:00 to 15:30
DL 09/DL 10 - Propaedeutics in Dry Eye / Dry Eye Treatment	08/20/21	14:00 to 15:30 16:00 to 17:30
WL 29 - IOL Scleral Fixation (Yamane Technique) - Group 4	08/20/21	16:00 to 17:30
WL 30 - Pterygium with amniotic membrane and biological glue	08/20/21	16:00 to 17:30
WL 31 - DALK (Deep Anterior Lamellar Keratoplasty)	08/20/21	16:00 to 17:30



CONFERENCES

August 19th

Grand Auditorium

16:00 - 18:00

AWARDS

August 20th

Grand Auditorium

18:30 - 19:30

Come and celebrate the scientific highlights of the event with a series of cash prizes and lots of enjoyment!

OPHTHALMOLOGY ASSISTANT COURSES

August 19th to 21st

Mezzanine 07

Day 08/18 | 09:00 - 10:30

MODULE 01 - INTRODUCTION

09:00 - 09:15: Waiting Room: Operation and Routine in Major Clinics.

09:15 - 09:30: Anatomy and Physiology.

09:30 - 09:45: Anatomy and Physiology.

09:45 - 10:00: Introduction to Cataract and Refractive Outpatient Examinations.

10:00 - 10:15: Surgical Center 1: Preoperative and Postoperative Cataract and Refractive.

10:15 - 10:30: Surgical Center 2: Surgical Supplies, Paramentation and Instrumentation in Cataract and Refractive Surgery.

Mezzanine 07

Day 08/18 | 11:00 - 12:30

MODULE 2 - COMPLEMENTARY EXAMINATIONS

11:00 - 11:15: Corneal Topography / Corneal Tomography.

11:15 - 11:30: Specular Microscopy / Pachymetry.

11:30 - 11:45: Optical and Ultrasonic Biometry.

11:45 - 12:00: Additional Exams: Retinal and Glaucoma Pam / Us / OCT.

12:00 - 12:15: Aberrometry.

12:15 - 12:30: Round Table Disucssion.

Mezzanine 07

Day 08/18 | 14:00 - 15:30

MODULE 3 - CATARACT

14:00 - 14:15: Cataract Surgery from the Physician's Point of View: Routine that the Team Must Know.

14:15 - 14:30: Equipment Used in Cataract Surgery: Phacoemulsifier, Vitreophage, and Femtosecond Laser.

14:30 - 14:45: Infection Prophylaxis in Cataract Surgery.

14:45 - 15:00: Cataract Surgery from a Nursing / Assistant Perspective: Routine That the Team Should Know.

15:00 - 15:15: Cataract Surgery for Refractive Purposes: IOLs and New Technologies - The Assistant's Role.

15:15 - 15:30: Round Table Discussion.

WL 6

Day 08/20 | 14:00 - 15:30

MODULE 4 - DRYLAB

14:00 - 14:20: Drylab: Topography.

14:22 - 14:40: Drylab: Tomography.

14:40 - 15:00: Drylab: Specular Microscopy.

15:00 - 15:20: Drylab: Optical Biometry.

15:20 - 15:30: Question and Answer.

WL 6

Day 08/20 | 16:00 - 17:30

MODULE 5 - DRYLAB

16:00 - 16:20: Drylab: Pachymetry.

16:20 - 16:40: Drylab: Auto-Refractor and Pneumatic Tonometry.

16:40 - 17:00: Drylab: IOL Assembly and Cataract Surgical Materials - Boxes.

17:00 - 17:20: Drylab: Refractive Surgical Materials, CXL.

17:20 - 17:30: Question and Answer.

Mezzanine 05

Day 08/21 | 09:00 - 10:30

MODULE 6 - REFRACTIVE SURGERY

09:00 - 09:15: Refractive Surgery from the Physician's Point of View: Routine That the Team Should Know.

09:15 - 09:30: Understanding Excimer Laser: Operation, Calibration, Data Entry.

09:30 - 09:45: Microkeratome: Care, Maintenance and Importance of the Assistant.

09:45 - 10:00: Understanding Femtosecond Laser: Operation, Calibration, and Programming.

10:00 - 10:15: Keratoconus: Ring Implantation and Crosslinking.

10:15 - 10:30: Question and Answer.

Mezzanine 05

Day 08/21 | 11:00 - 12:30

MODULE 7 - ACCREDITATION / BILLING

11:00 - 11:15: Invoicing.

11:15 - 11:30: Sterilization and Care of Ophthalmic Materials.

11:30 - 11:45: Accreditation in Healthcare and Ophthalmology.

11:45 - 12:00: Safe Cataract and Refractive Surgery: Protocols.

12:00 - 12:15: How to Prepare the Team for Accreditation.

12:15 - 12:30: Round Table Disucssion.



CLOSING REMARKS

August 21st

Grand Auditorium

12:30 - 13:30

**Enjoy the moments of
relaxation to satisfy
your longing and
exchange that golden
idea that is worth
more than a hundred
lessons!!**

AUTHORS

ASHVIN AGARWAL

Executive Director. Head of Clinical Services. Chairman of the clinical board of Dr. Agarwal's Group Eye Hospital.



PRIYA NARANG

Director of Narang Eye Care & Laser Centre, Ahmedabad, India. Email: narangpriya19@gmail.com.



SECTION EDITOR AND GENERAL EDITOR OF OFTALMOLOGIA EM FOCO

BRUNA VENTURA

Master's degree from the Federal University of Alagoas (UFAL). PhD from the Federal University of São Paulo (Unifesp). Coordinator of the Specialization Course in Ophthalmology of the Altino Ventura Foundation (FAV). Coordinator of the FAV Cataract Department.



“Os estudos comparativos entre o AVA e o SAP demonstraram uma capacidade equivalente de detectar todas as formas de defeitos no campo visual”

ADVANCED VISION ANALYZER (AVA):

Virtual reality perimeter

Financial disclosure: authors have no direct financial interest in the product.

In the current ongoing pandemic situation of Covid-19, global health is an aspect that has been emphasized by the leading health authorities and institutions across the globe including the World Health organization. There is a growing concern of preventing the spread of infectious diseases on one hand and offering the best available healthcare facilities to the segment of individuals that suffer from other chronic diseases and disorders. Glaucoma is one of the leading causes of blindness and early detection is of paramount importance to curtail its effect on visual fields of the patient.

Standard automated perimetry (SAP) is the gold standard for evaluating the visual fields of a glaucoma patient. Needless to mention, these SAP devices occupy a great amount of physical space and they need a dedicated dark room to perform the perimetry procedure. Virtual reality is an established and a growing technology with various applications that places the viewers inside a virtual experience without the traditional user interface. Advanced visual analyzer (AVA) exploits the virtual reality platform to offer various advantages to the patients as compared to the SAP.

ADVANCED VISION ANALYZER (AVATM) DEVICE & COMPONENTS:

AVATM by ELISAR vision technology is a battery-powered virtual reality auto-perimeter that comprises of a head mounted device, a patient response button which is a hand-held device and an Android tablet that serves as a controller to perform, record and analyze the test program (Figure 1). The head mounted device (HMD) is lightweight and it allows a high degree of flexibility in patient position and testing in the supine position too if deemed necessary. The HMD comprises of an optical and display system that has an LED screen and an eye tracking system. AVA offers white-on-white perimetry with the stimulus intensity that ranges from 0-40 de-

cibels (dB). The patient response button is connected to the HMD through wire and the patient presses the PR button upon visualization of the stimulus (Figure 2). The tablet incorporates software that helps to regularly update data on the cloud, which is the backend server. This feature commissions regular seamless software updates that can be performed remotely without the need for physical inspection. The device can be connected wirelessly to the printer and the reports can be delivered by email. Additionally, previous test results can be retrieved from cloud storage by feeding the patient details. AVA allows adjustment for the refractive error and the data regarding the same are also fed into the system. The clinical data recorded and stored on AVA is encrypted and is therefore secure. As the device is portable, it does not need a dark room to perform the test and also obviates the need to occlude the fellow eye. The device automatically adjusts and records the visual field data of each eye.

CLINICAL TESTING & REPORT:

The visual field test is performed with Goldman III stimulus size and fixation monitoring is done with Heijl-Krakau tests. The visual field assessment patterns available on AVA are 24-2 and 30-2 program whereas the testing strategies that are available are supra-threshold, full threshold, Elisar Zest and Elisar Fast. An integral eye tracker incorporated in AVA, provides a live feed of the tested eye on the test controller. The



Figure 1 - The image showcases the AVA device that comprises of a headset, patient response button and the test controller



Figure 2 - The image depicts the virtual reality headset on a patient

advanced infrared tracking technology allows patient monitoring and minimizes fixation loss. The device also possesses an inter-pupillary distance (IPD) adjustment capability that can assure accurate field measurement.

The printed test report provides the following details (Figure 3):

1. Patient information, test type, test duration.
2. Absolute threshold values and gray scale pattern.
3. Gradient plot based on the threshold results obtained.
4. Reliability parameters such as False Positive, False Negative and Fixation loss.
5. Defect significance and global indices that are compared with a normative database built specifically for AVA.
6. The Global indices (GI) that represent summary of all the sensitivity values produced by the test. The GI test-data that are provided in detail are Total Deviation, Pattern deviation and Glaucoma hemi-field test (GHT). As in a SAP, GHT in AVA allows comparison of visual field defects across the horizontal axis the response being denoted as 1) Within normal limits, 2) Borderline and 3) Outside normal limits.

The comparative studies between AVA and SAP when performed demonstrated equivalent ability to detect all forms of visual field defects. The report generated by the device meets international standards and adheres to the format that ophthalmologists are accustomed to thereby minimizing the learning curve. The functional and clinical trials have demonstra-

ted the utility of AVA as an imperative tool to detect and analyze visual field defects in patients of all age groups. The benefit that is of paramount importance with AVA is its ability to perform the tests in patients regardless of them being physically disabled or bedridden. To summarize, AVA has set a new paradigm to measure, record and analyze visual field defects concurrently allowing the need to meet global demand for quality eye care in the era of digital health. In the current COVID-19 pandemic situation, AVA can prove to be crucial diagnostic option for patients whose health condition would be threatened by bringing them to a central testing site. The trained personnel can perform the test for these patients at home and the data can be emailed to the ophthalmologist. Additionally, AVA also allows adequate physical distance to be maintained during the visual field assessment test as the personnel who is conducting the test with the test-controller can stand away from the patient and monitor the test. To conclude, the authors feel that AVA virtual reality perimeter has a promising outlook towards serving the ophthalmic fraternity by providing visual

field assessment that is as accurate as SAP with the additional benefits of it being portable and reliable.

HIGHLIGHTS OF AVA VIRTUAL REALITY PERIMETER:

- Portable.
- No learning curve.
- Accurate detection of visual field defects.
- Cost effective as compared to standard perimeters.
- Useful in patients with postural defects & those who are bed-ridden.
- Offers screening & Threshold strategies. Visual field defect charting is equivalent to standard automated perimeters.
- Helpful in Rural areas for community screening.
- Useful in Covid-19 pandemic and thereafter as it allows maintaining social distancing as well as it enables patient to wear a mask and perform the perimetry procedure.

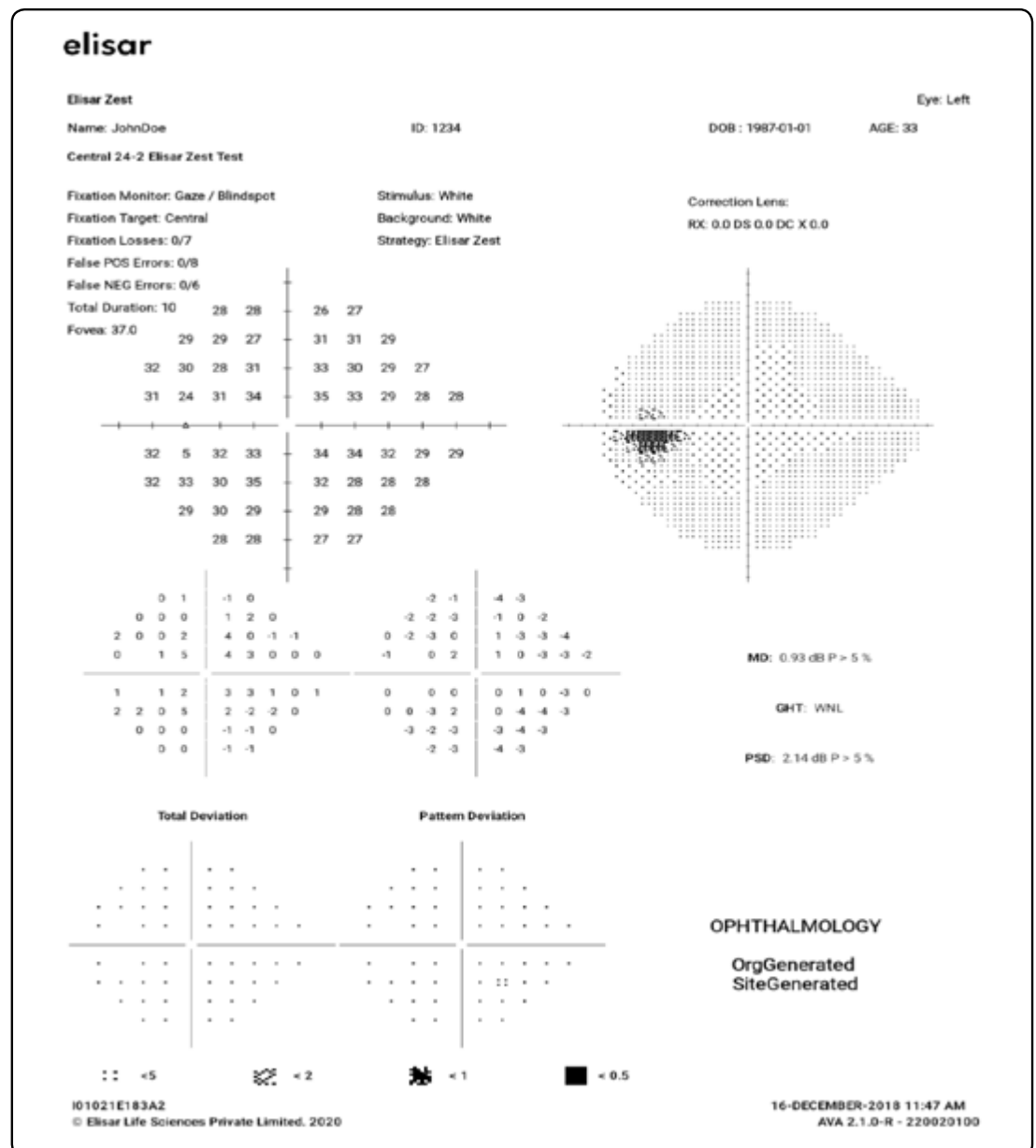
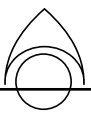


Figure 3 - The image depicts the visual field charting with AVA device



AUTHOR

ALESSANDRO ADAD JAMMAL

Specialist in Glaucoma through Universidade de Campinas (Unicamp). Research scientist at Duke University, U.S.A. Doctoral candidate through Universidade de Campinas (Unicamp).



SECTION PUBLISHERS

FÁBIO DAGA

Specialist in glaucoma, cataract and refractive surgery, with training from the University of California, San Diego, Duke University, Unifesp and Santa Casa de São Paulo. Medical assistant at Universidade Federal de Goiás. Co-editor of OF Glaucoma.



VICTOR CVINTAL

Glaucoma sector head at the Instituto de Oftalmologia Tadeu Cvintal, São Paulo, SP. Glaucoma Research Fellowship through the Wills Eye Hospital, Philadelphia, USA. Glaucoma Sector Head at FMABC. Glaucoma Editor of Oftalmologia em Foco.



“...the large quantity of digital complementary exam data available has turned Ophthalmology into a promising field for the application of many of these techniques...”

UNDERSTANDING THE USE OF ARTIFICIAL INTELLIGENCE IN OPHTHALMOLOGY

Ophthalmologists are used to technology. Computerized processes are present in their daily clinical practice: from the autorefractor in order to help prescribing visual correction, to 3D monitors to help in the surgical treatment of complex ocular pathologies, including the numerous automated diagnostics tools such as OCT and standard automated perimetry.

Recently, a new technological frontier has opened, with artificial intelligence (AI) as the basis of this new industrial revolution. However, general ophthalmologists are not expected to have a general background in computer science, and many of the traditional critical analysis skills for clinical studies do not always apply directly to AI studies.

On the following pages, we spoke with Dr. Alessandro Jammal, researcher at Duke University, USA about AI to facilitate the understanding of some concepts used in the growing number of studies that use this new technology.

Firstly, why has AI started to be used in Ophthalmology only nowadays?

In reality, AI algorithms have been used in Ophthalmology for more than two decades; the concept of AI, in its broader meaning, was developed in 1950 by British Alan Turing, whom many should know from the film “The Imitation Game” from 2013. However, more recently, the exponential growth of computational power and the large quantity of digital complementary exam data available has turned Ophthalmology into a promising field for the application of many of these techniques that have been developed for various years.

What is the difference between AI, machine learning (ML) and deep learning (DL)?

These are concepts which are related, but they are not the same thing (Figure 1). Artificial intelligence is a very broad concept, defined as a project to assemble a non-human intelligence, that is, how can we make machines do some activities that we think need intelligence. ML is a way of doing this, using machines to learn through data, to improve a specific task. ML includes multiple logistic regression calculations to arrive at a prediction. For example, decision trees for risk stratification and prognosis in which ways of dividing a population with a disease (for example, the presence of a clinical sign or abnormal exam result, or not) are identified in an automated way. Now, DL is an ML subtype that uses multiple layers of computation to arrive at a prediction. The term “deep” in DL is nothing more than layer upon layer of computing. The more layers, the more complex (or deeper) the model is and a greater computational power is needed. Currently, the standard choice for more complex tasks such as the image evaluation (computer vision) are more sophisticated models called neural networks, the convolutional neural networks (CNN) which have several nodes (or neurons) that break down and recombine the information given to the model and perform multiple mathematical calculations.

“Machine learning” can be translated into Portuguese as, “aprendizado de máquina”.

How can you make a machine to learn?

There are two main ways of making a machine

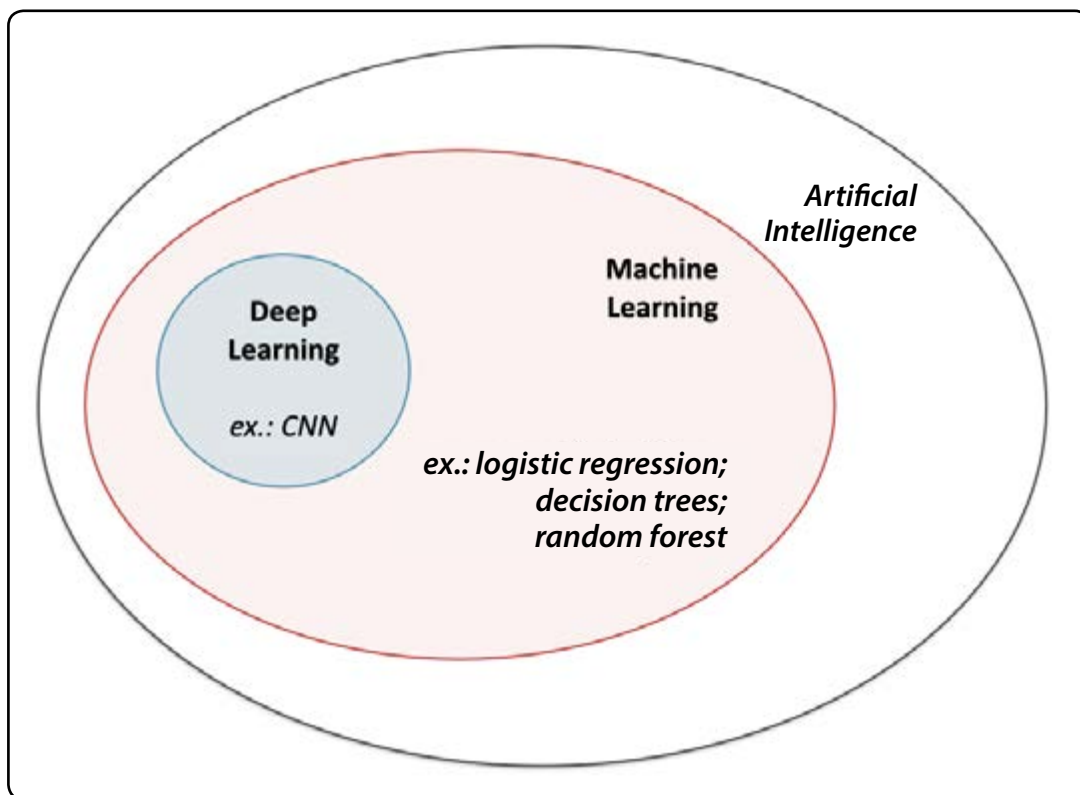


Figure 1 - Diagram demonstrating the organization of the classification of artificial intelligence algorithms

learn: “supervised” and “unsupervised”. Supervised means that in the sample each data will have a corresponding label, for example, the presence of diabetic retinopathy or not. These classifications may be made in a number of ways, through evaluation by a panel of specialists, or confirmation through another reference diagnostic exam. It is expected that this classification is the best possible, otherwise the model is going to “learn incorrectly”, since it is going to use false information as a reference. These are ultimately the most commonly used models. The unsupervised models do not have this prior classification and it is expected that the mathematical operations that compose the model will be able to learn patterns and characteristics that differentiate the data in the sample. There are some known statistical methods that use unsupervised methods, such as “principal component analysis (PCA)”, which has been used for several years. Nevertheless, during the training process, several settings need to be pre-specified. These settings are called “hyperparameters” and define how the AI system learns from the data.

What are training, validation, and test samples?

As I mentioned, the collected data sets are usually divided in training, validation, and test datasets. Firstly, we randomly save a test sample that is representative of the population in which we are testing the algorithm. The rest (and usually the greater part) is used to train the algorithm. As the determination of the correct hyperparameters require broad trial and error, a subset of data from the large training group is used for “validation”, that is, it is separated to adjust these “hyperparameters.” Once the algorithm is trained with a training sample, adjusted by the validation sample, the algorithm is then applied to the test sample and the diagnostic capacity is evaluated. Because of the differences in terminology between the studies, the “validation dataset”, sometimes, is called the “adjustment” dataset; and the “test” dataset is sometimes called the “clinical validation dataset”, so you have to pay attention to the nomenclature used by each study. It is important to evaluate if the study does not allow data from the same patient “leak” between groups, that is, that the same patient has photos in more than one of the groups. It is as if we were to take a test already knowing the questions that will be on it, which generates an overestimation of the

algorithm performance, which is unreal.

For artificial intelligence, is it necessary a very large quantity of data?

No, not necessarily, but it is preferable, yes. Similar to any statistical analysis, AI performance increases to a certain extent based on the volume of training data. For ML techniques, an amount of data in the order of hundreds, and for DL, tens of thousands, is expected. There are methods that are generally used to “augment the data” artificially, which basically consists of generating new images with a change of brightness and contrast for a few rotations in their position to make them a little different from the original image. This allows the model to learn that despite some differences in the image being present (for example, a retinography with a certain diffuse opacity), its classification will not change. Another option that has been used is transfer learning. In this technique, an algorithm that had been trained previously for another task with more data may be adapted to a specific task. The most used are those developed from the “ImageNet dataset”, which was an online competition to identify more than a thousand categories (different animals and objects) in more than 1 million images on the Internet. When we use one of these pre-trained algorithms, we are borrowing the first layers of the model, which are used to identify borders and textures that are common in any type of image, and “retrain” the last layers with a more specific “dataset” for the task we want, such as background photographs. This prevents the need for more data to develop coarser image evaluation skills, i.e., starting from zero.

How do you know if the machine learned correctly?

The performance of the AI in the test dataset is evaluated in comparison with a reference pattern, which must be a widely accepted diagnostic method. The reference pattern is vital to validate an algorithm and is often based on the concordance of several evaluators, a panel of trained subspecialists or diagnostic centers. The diagnostic performance of an algorithm

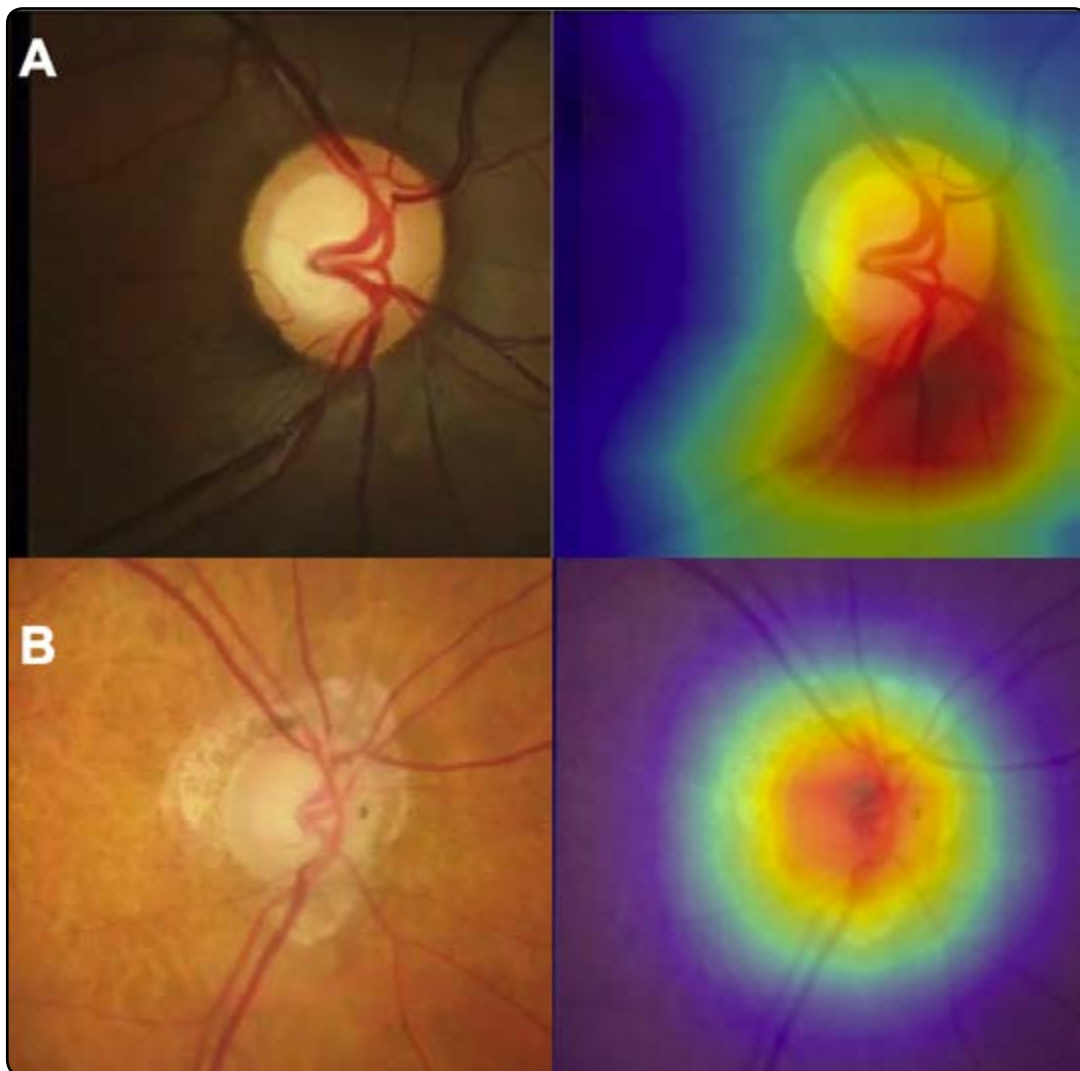


Figure 2 - Examples of heat maps for deep learning algorithms. In A, the algorithm was trained to predict the thickness of the peripapillary nerve fiber layer from the optic disc photos. It is observed that the heat map correctly highlights the area of the optic disc and the adjacent area with nerve fibers as the most important regions for the predictions. In B, the algorithm was trained to predict the least thickness of the neural rim from the opening of the Bruch membrane, the heat maps correctly highlight the areas of excavation and neural rim. Source: Author's archive. The algorithm in A was described by Medeiros FA, Jammal AA, Thompson AC. From Machine to Machine: An OCT-Trained Deep Learning Algorithm for Objective Quantification of Glaucomatous Damage in Fundus Photographs. *Ophthalmology* 2019;126(4):513-21; and the algorithm in B was described by: Thompson AC, Jammal AA, Medeiros FA. A Deep Learning Algorithm to Quantify Neuroretinal Rim Loss From Optic Disc Photographs. *Am J Ophthalmol* 2019;201:9-18.

is evaluated using known statistical methods, such as concordance coefficients, the evaluation of sensibility and specificity, accuracy, positive predictive value, negative predictive value, and the area under the ROC curve. For results with continuous values (such as the prediction of the thickness of the nerve fiber layers from photos), generally measurements of accuracy, such as mean absolute errors and mean quadratic error are also usually reported. The absolute mean error (average of the differences between the algorithm and the reference value), for example, must be closer to zero for the model to be absent of error. A criticism of AI methods for diagnosis is that classification

takes place through millions and billions of mathematical operations, which makes them difficult to understand. As such, some have labeled these methods as “black box”, as it is difficult to illustrate what happens inside them. Some methods, such as the use of heat maps (Figure 2), can show the locations of the image that were most important for the algorithm classification and these maps can be critically analyzed. For example, if an algorithm proposes to diagnose diabetic retinopathy through photos, it is expected to highlight areas of bleeding and exudates, which are part of the diagnosis of the disease.

What are the main limitations for AI?

Technically, the main factor is the lack of quality data, with reliable annotations on the presence of certain pathologies. As previously stated, the machine is only as good as the reference pattern that teaches it. Another important factor is the concept of the capacity to generalize the results. This means that an algorithm should function not just for the sample that was used to train it but should also allow it to be used on patients with different characteristics in a sufficiently heterogeneous population. The limitations of algorithms to detect skin cancer are well known, for example, those that perform significantly worse in black patients than in white patients, because the training sample was not heterogeneous enough. This prevents such an algorithm from being used on a population with great miscegenation, such as in Brazil. Finally, physicians may understandably be reluctant to accept the results and clinical decisions made through AI algorithms that are not fully understood. In addition, real-world implications include legal liability and additional costs to the healthcare system when using AI in clinical decision making. Future studies should focus on validating algorithms with real world data from different populations and applied in various types and versions of instruments.

Are there already approved algorithms for use in clinical practice?

Yes. The clinical implementation began with the first bottom-eye camera equipped with FDA-approved AI for tracking diabetic retinopathy in 2018 (IDx-Dr; IDx Technologies Inc., Coralville, IA, USA), but it is not yet available in Brazil.

Suggested Reading:

Ting DSW, Lee AY, Wong TY. An Ophthalmologist's Guide to Deciphering Studies in Artificial Intelligence. *Ophthalmology* 2019;126(11):1475-9.

AUTHORS

**ROBERTO DAMIAN
PACHECO PINTO**

Ophthalmology Residency - Unicamp. Board Certified - Brazilian Council of Ophthalmology. Cataract, refractive and Corneal surgery - Unicamp. Ph.D. and post-doctorate - Unicamp.



MONICA ALVES

Collaborative professor - Department of Ophthalmology and Otorhinolaryngology - Unicamp



SECTION PUBLISHER
RICHARD YUDI HIDA

Ocular Surface Study Group - University of São Paulo (USP). Surgical Optics - Federal University of São Paulo (Unifesp). President of the Brazilian Laser and Ophthalmic Surgery Society (BLOSS), 2020.



“Chronic inflammation of the surface, which is affected by the severity of blepharitis, from both allergy and dry eye, such as factors like epithelial microtrauma, may lead to the development and progression of keratoconus”

KERATOCONUS AND OCULAR SURFACE

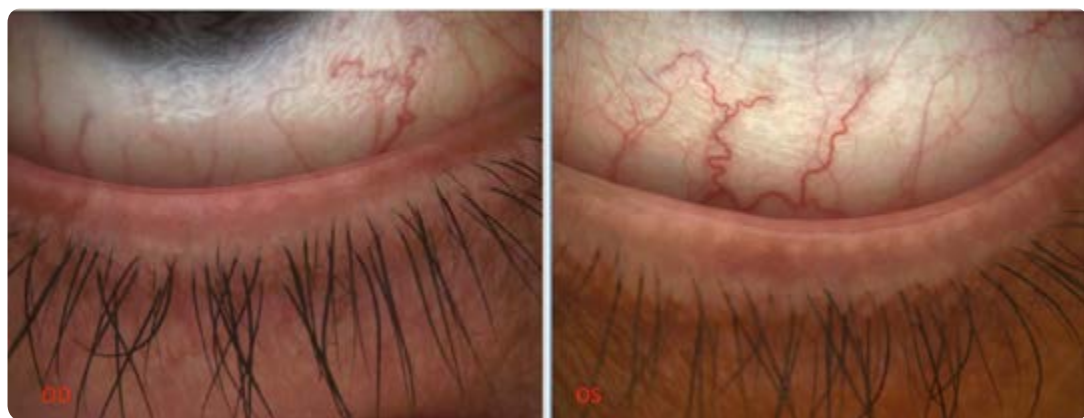

Figure 1 - Slit lamp examination of the anterior and posterior blepharitis reveals conjunctival hyperemia, erythema, and telangiectasia of the lid margin, meibomian glands with obstructed ducts, without any secretion during expression

Meibomian gland dysfunction (MGD), dry eye disease (DES), and keratoconus are frequent pathologies in everyday practice. In this article, we have shown how these diseases can correlate.

MEIBOMIAN GLAND DYSFUNCTION AND DRY EYE

MGD is considered the most common cause of dry eye leading to evaporative DES.¹

MGD related to DES may be diagnosed clinically through the expression of the glands on the lid margin, slit lamp evaluation (**Figure 1**), and tear film break-up time (BUT) (invasive or non-invasive). With the advance of technology, we have an improved propaedeutic arsenal, and we can also evaluate the meibomian glands (MG) through direct methods, such as meibography, which uses transillumination or infrared light (IR) to visualize the meibomian glands.² **Figure 2** shows severe MG loss with the superior lid with no functional glands and the inferior lid with more than 50% loss. Another objective test is the tear meniscus height, assisted by Oculus Keratograph 5M (OCULUS, Inc) (**Figure 3**). Normal meniscus height is

thought to be greater than 0.2 mm.

KERATOCONUS AND DRY EYE

Carracedo et. al.³ reported that patients with keratoconus have more severe symptoms of dry eye and great instability of the tear film. Additionally, blepharitis occurs more frequently in patients with keratoconus when compared to healthy individuals. Blepharitis is associated with ocular pruritus, which is one of the main etiological factors of keratoconus,⁴ as we will discuss below.

Studies that evaluate the ocular surface in patients with keratoconus have shown normal Schirmer test in comparison with the control group. However, 70% of patients with keratoconus have shown reduced BUT, and 81.5% have complained of symptoms of fatigue, irritation, and foreign body sensation. Additionally, fluorescein and Rose Bengal staining scores were worse when compared to control group.⁴

Prior studies have shown that blepharitis occurs more frequently in patients with keratoconus.^{4,5} With posterior blepharitis being the main cause of evaporative dry eye. It is a fact that keratoconus, MGD, and DES commonly coexist.

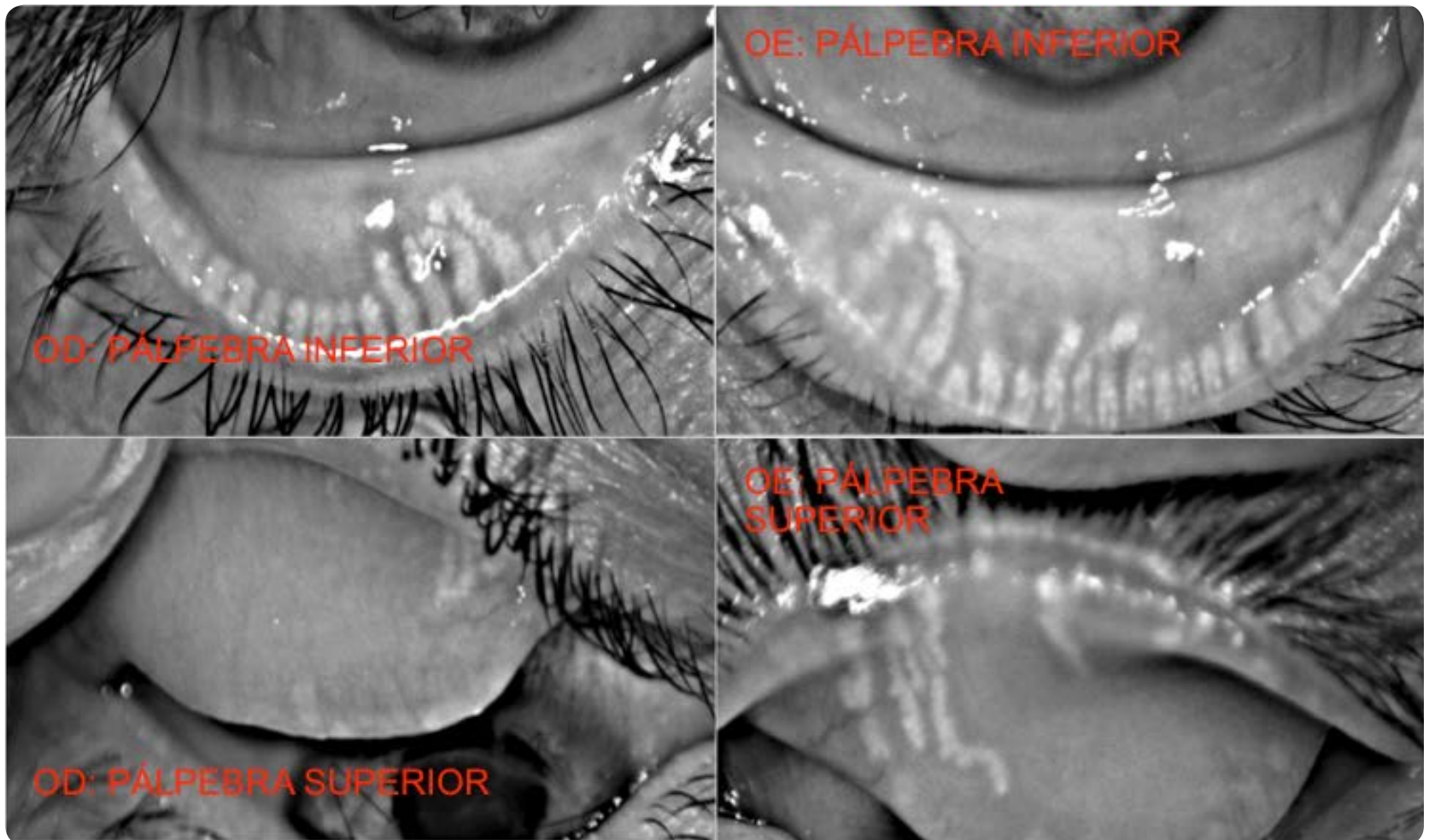


Figure 2 - Superior and inferior meibography reveals severe loss of MG in both eyes. The superior lid is found without any glands and the inferior lid has 50% loss of MG

PRURITUS AND KERATOCONUS

A case-control study showed that there was an association between keratoconus and atopy, such as ocular pruritus (itching) and family history. However, in the multivariate analysis, the authors found that just the ocular pruritus is a significant predictive factor for keratoconus. They also concluded that atopy may contribute to keratoconus, probably due to the ocular itching combined with atopy.⁶ Another study demonstrated that ocular pruritus leads to a six-fold increase in the risk of keratoconus.⁷

One of the pathophysiological factors of ocular pruritus as an etiological factor for keratoconus is in the epithelial microtrauma associated with the release of inflammatory mediators (such as interleukin-1), which can trigger Fas-ligand expression by keratocytes. Epithelial trauma also releases Fas-ligand directly. When Fas-ligand binds with a keratocyte Fas receptor, apoptosis is induced, reducing the number of keratocytes in the cornea with keratoconus.⁸

Nevertheless, the resulting microtrauma from the pruritus increases MMP-13 levels (metalloproteinases 13), IL-6 (interleukin-6), and TNF- α (Tumor necrosis factor). Itching is a factor that triggers the progression of the disease through several mechanisms, including the stimulus for inflammation.⁹

MGD AND KERATOCONUS

Patients with keratoconus present a greater MG loss when compared to healthy individuals. MGD can show the following symptoms: bur-

ning, irritation, photophobia, blurred vision, and hyperemia. Soon, symptoms control may reduce the tendency for eye rubbing.⁵

Also, chronic inflammation and its mediators, can present be present in individuals with concomitant anterior blepharitis. It may play an important role in keratoconus and its progression, since the inflammatory mediators are also involved in its pathophysiology.¹⁰

Matsumoto et. al. demonstrated the importance of suppressing inflammation during the



Figure 3 - Lacrimal meniscus height increased in both eyes (greater than 0.2 mm). It is a compensatory mechanism for evaporative dry eye

treatment of MGD and anterior blepharitis. It was shown that the tear film BUT, fluorescein staining, and inflammatory cell density (confocal microscopy) significantly improved in the group that received anti-inflammatory therapy.¹¹

Chronic inflammation of the surface, which is affected by the severity of blepharitis, from both allergy and dry eye, such as factors like epithelial microtrauma, may lead to the development and progression of keratoconus. Dia-

gram 1 shows the possible mechanism of how MGD and DES are related to etiopathogeny and the progression of keratoconus.

It is also important to remember that, in older individuals, the classic signs of atopic conjunctivitis are not always present, so the investigation chronic pruritus may be mandatory. MGD and DES are one of the main causes in this group.

THE IMPORTANCE OF THE TREATMENT

The treatment for keratoconus needs to include early diagnosis, regular monitoring, and treatment of environmental factors. Along the same line, the effective management of MGD and DES is essential in reducing pruritus and the mechanical stress of the vulnerable corneas.

The objective of improving the ocular surface, with the reduction of ocular pruritus and inflammation control, must be constantly maintained in keratoconus patients.

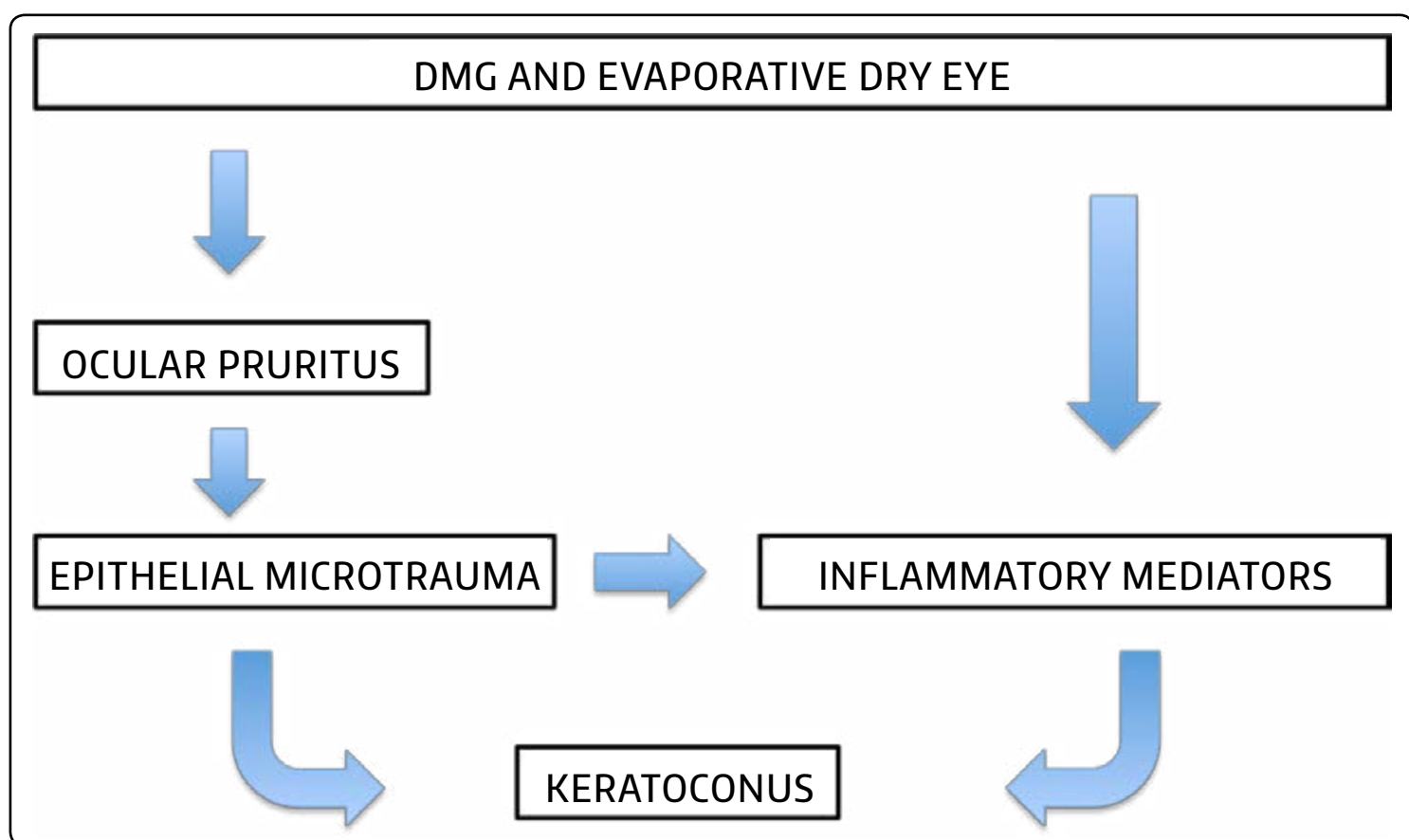


Diagram 1

REFERENCES

1. Arita R, Itoh K, Inoue K, Amano S. Noncontact infrared meibography to document age-related changes of the meibomian glands in a normal population. *Ophthalmology* 2008;115:911-915.
2. Arita R, Suehiro J, Haraguchi T, et. al. Objective image analysis of the meibomian gland area. *Br J Ophthalmol* 2014;98:746-755.
3. Carracedo G, Recchioni A, Alejandre-Alba N, et. al. Signs and Symptoms of Dry Eye in Keratoconus Patients: A Pilot Study. *Curr Eye Res* 2015;40:1088-1094.
4. Mostovoy D, Vinker S, Mimouni M, et. al. The association of

- keratoconus with blepharitis: Keratoconus and blepharitis. *Clin Exp Optom* 2018;101:339-344.
5. Mohamed Mostafa E, Abdellah MM, Elhawary AM, Mounir A. Noncontact Meibography in Patients with Keratoconus. *J Ophthalmol* 2019;2019:2965872.
6. Bawazeer AM, Hodge WG, Lorimer B. Atopy and keratoconus: a multivariate analysis. *Br J Ophthalmol* 2000;84:834-836.
7. McMonnies CW. Mechanisms of rubbing-related corneal trauma in keratoconus. *Cornea* 2009;28:607-615.
8. McGhee CNJ. 2008 Sir Norman McAlister Gregg Lecture: 150 years of practical observations on the conical cornea--what have we learned? *Clin Experiment Ophthalmol*

- 2009;37:160-176.
9. Galvis V, Sherwin T, Tello A, et. al. Keratoconus: an inflammatory disorder? *Eye* 2015;29:843-859.
10. Knop E, Knop N, Millar T, et. al. The international workshop on meibomian gland dysfunction: report of the subcommittee on anatomy, physiology, and pathophysiology of the meibomian gland. *Invest Ophthalmol Vis Sci* 2011;52:1938-1978.
11. Matsumoto Y, Shigeno Y, Sato EA, et. al. The evaluation of the treatment response in obstructive meibomian gland disease by in vivo laser confocal microscopy. *Graefes Arch Clin Exp Ophthalmol Albrecht Von Graefes Arch Klin Exp Ophthalmol* 2009;247:821-829.

AUTHOR

CARLOS EDUARDO G. PEREIRA

Master's degree through the Federal University of Goiás. Fellowship in retina and vitreous through Santa Casa de São Paulo. Ophthalmologist at the Instituto Panamericano de Visão (Panamerican Vision Institute)



DAVI CHEN WU

Assistant physician at the Retina and Vitreous Department of the Irmandade Santa Casa de Misericórdia de São Paulo.



SECTION PUBLISHER

RICHARD YUDI HIDA

Ocular Surface Study Group - University of São Paulo (USP). Surgical Optics - Federal University of São Paulo (Unifesp). President of the Brazilian Laser and Ophthalmic Surgery Society (BLOSS), 2020.



CONTROVERSIES IN REFRACTIVE LENS EXCHANGE (RLE):

point of view from retina surgeon

Modern cataract surgery allows, not just the removal of cataracts, but also the treatment of refractive errors. However, some factors, from the perspective of retina specialists should be considered.

- **Acceptable refraction outcomes:** the FACT trial reported a refraction error of less than 1 diopter in 91% of phacoemulsification cases, with or without the assistance of femtosecond laser.¹
- **Increase risk of retinal detachment (RD):** despite good refraction outcomes and low rates of complications, pseudophakic patients present a four-fold increase in the risk of RD, according to a 200 thousand patient study conducted in Denmark.³

The rates of complication are controversially acceptable, however, potentially severe: even with a good retinal mapping and blockage of ruptures, such as those found in figure 1.

- **Surgical complications exacerbate the risk of RD:** a study involving problems with the posterior capsule on high-volume Swedish surgeons (more than 500 surgeries

per year) shows rates of 0.58%.² It is known that posterior capsule ruptures, associated with vitreous loss, are related to the increase the risk of RD. Patients who have had a posterior capsule rupture present a 42 times greater risk of RD in the first three months after surgery when compared to those who presented no complications.

- **Greater risk of RD in younger patients:** the younger the patient submitted to RLE, the greater the risk of RD: patients under 60 years of age present a 5.12 times increased risk of RD, while for those over 80, the risk is at 0.16%.⁴
- **The myopic population has a greater risk of RD:** this occurs even in patients who will

“...pseudophakic patients present a four-fold increase in the risk of RD, according to a 200 thousand patient study conducted in Denmark”

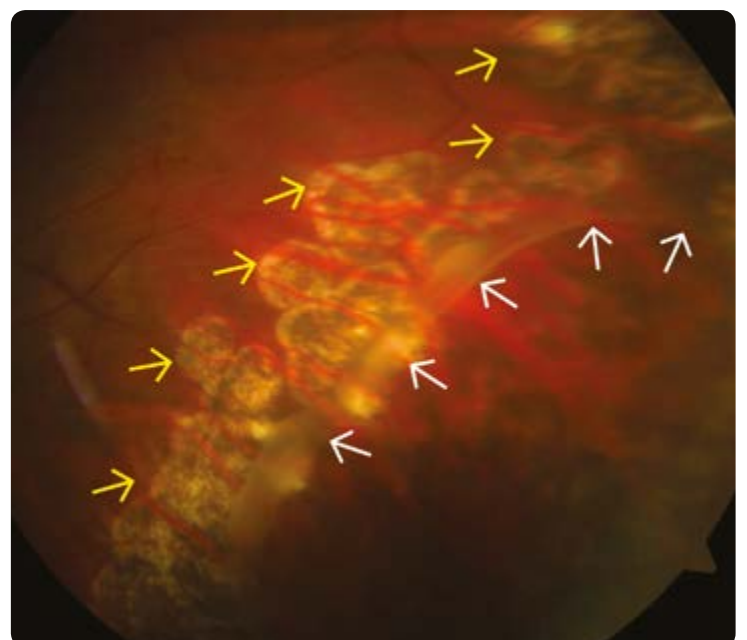


Figure 1 - Yellow arrows showing photocoagulation scarring and white arrows showing the edge of the detached retina

not be submitted to surgery. The 50-year-old myopic patient already showing signs of presbyopia, despite being a “good” candidate for intraocular lens implantation, is also one of those who present a higher risk for DR.

• **Pre-operative macular evaluation:** another increasingly frequent issue is the evaluation of the macula for this modality of surgery. OCT is a very useful screening preoperative tool. In a retrospective study of 401 eyes, 26.7% showed abnormal OCT and 65.42% of those changes have gone unnoticed at routine funduscopy examination.⁵ Another study found that 9.21% of patients with macular alterations at the OCT had not been detected at the funduscopy: in this study, three months after the procedure, patients had not shown worse outcomes in terms of vision when compared to patients with

normal OCT. Additionally, we need to take into account that several retinal diseases present good visual acuity in the initial phases of the disease, such as in the example of the patient in **figure 2**. The patient had 20/20 vision even with alterations in the OCT and progressed to 20/100 after secondary submacular hemorrhage due to Age related macular degeneration (ARMD) (**Figure 3**). In a study of 495 eyes with moderate ARMD, 32% de-

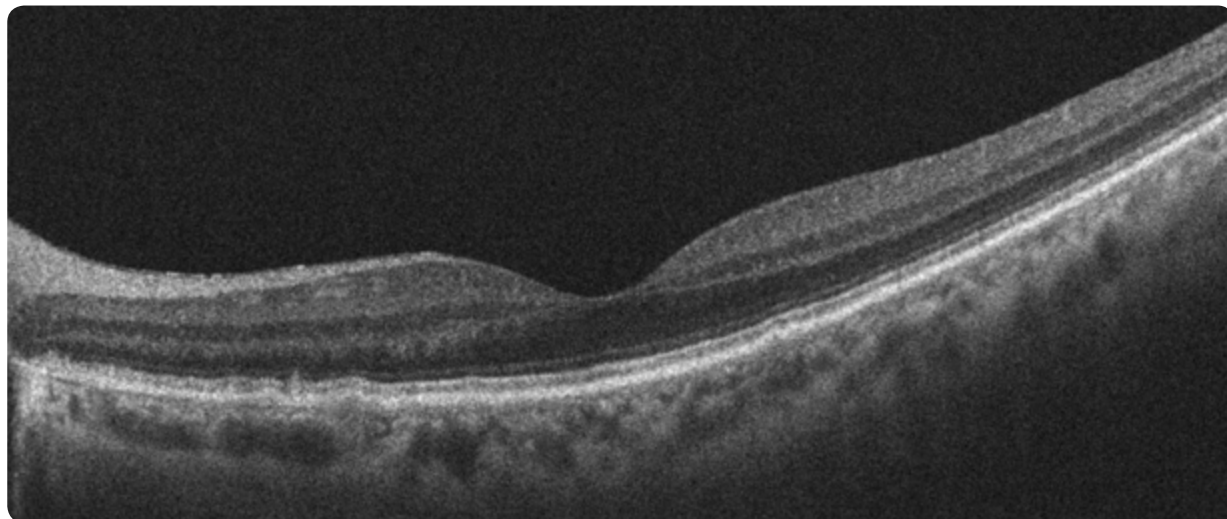


Figure 2

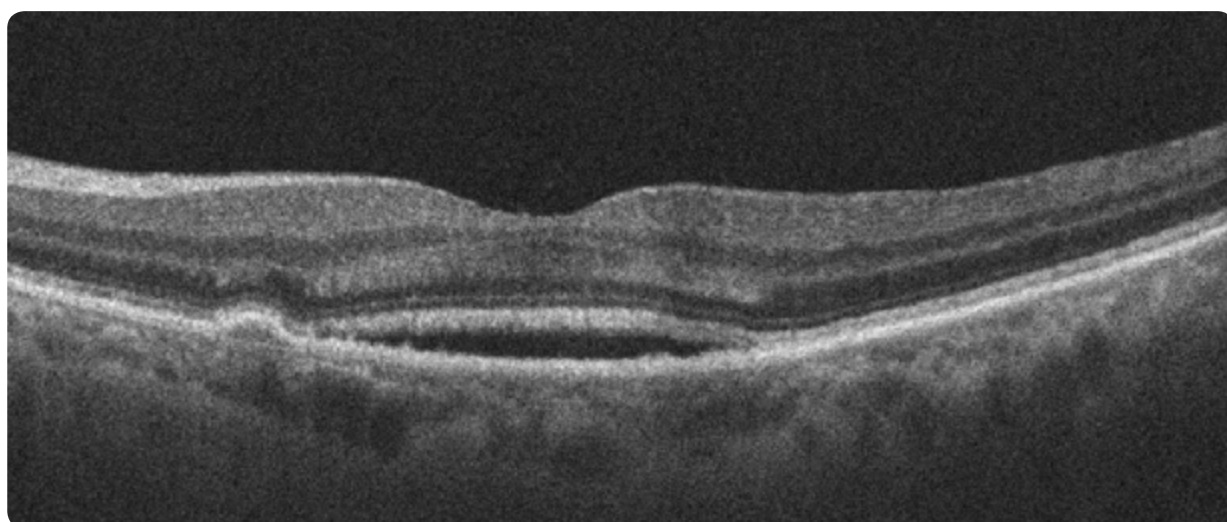


Figure 3

veloped an advanced form in two years. The risk factors for this progression are multifactorial and are still under investigation.⁶

Therefore, the long-term success of RLE or cataract surgery needs an excellent preoperative evaluation. This is when the ophthalmologist and patient must discuss the benefits and risks for independency of glasses after complete evaluation.

TAKE HOME MESSAGES

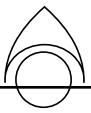
- Always discuss risks and benefits for RLE. Even the best surgeons experience complications!
- Request OCT and/or retina evaluation in all cases.
- Be conservative in multifocal lens implantations if the patient shows retinal diseases.
- Posterior capsule rupture and patients under 60 years old has higher risk of RD.

REFERENCES

1. Femtosecond Laser-Assisted Cataract Surgery Versus Phacoemulsification Cataract Surgery (FACT) A Randomized Noninferiority Trial Day CA, Burr JM, Bennett K, et. al. on behalf of the FACT group Ophthalmology Volume 127, Number 8, August 2020
2. Cataract surgery volumes and complications per surgeon and clinical unit: data from the Swedish National Cataract Re-

- gister 2007 to 2016. Zetterberg M, Montan P, Kugelberg M. et. al. Ophthalmology. 2020; 127: 305-314
3. Risk of pseudophakic retinal detachment in 202,226 patients using the fellow nonoperated eye as reference. Bjerrum SS, Mikkelsen KL, La Cour M Ophthalmology. 2013; 120: 2573-2579
4. Risk factors for retinal detachment following cataract surgery: the impact of posterior capsular rupture. Petousis V, Sallam AA, Haynes RJ, Patel CK, Tyagi AK, Kirkpatrick JN, John-

- ton RL. Br J Ophthalmol. 2016 Nov;100(11):1461-1465.
5. Preoperative spectral-domain optical coherence tomography in patients having cataract surgery. Abdelmassih Y, El-Khoury S, Gerofes S et. al. J Cataract Refract Surg 2018 May; 44(5):610-614
6. Prediction of Individual Disease Conversion in Early AMD Using Artificial Intelligence Schmidt-Erfurt U, Waldstein SM, Klimscha S et. al. Invest Ophthalmol Vis Sci 2018 Jul 2; 59(8): 3199-3208



AUTHOR

SAMARA B. MARAFON

Banco de Olhos of Porto Alegre Hospital. Oftalmocenter. Master in Surgical Sciences (UFRGS). Postgraduate Medical Education, University of Toronto, Canada.



SECTION PUBLISHER

LARISSA GOUVEA

Centro Amazonense de Oftalmologia, Manaus - AM. Donald K. Johnson Eye Institute, University of Toronto, Toronto - CA.



OPHTHALMOLOGICAL EMERGENCIES DURING THE PANDEMIC:

my experience and the lessons that we've learned

It has been one year since the Covid-19 pandemic started and completely altered the world scenery. To deal with the virus, human and hospital resources were reorganized, and extreme measures were taken to not only protect the wellbeing of the population, but also to meet the demands of those infected by the disease. In the healthcare sector, elective appointments were markedly reduced or suspended for an indefinite period. Urgent services and intensive care units, on the other hand, remained open and were broadened. In Ophthalmology emergency rooms, changes were also observed, but with their distinct characteristics.

At a time in which most medical services were adjusting to care for a greater number of patients, we were surprised by a drastic change in the search for eyecare and in the presentation pattern of the diseases. In the initial months of the pandemic, the number of patients in the emergency department reduced considerably, so that the medical staff usually able to consult on more than 100 patients per day was reduced by half. We estimate a reduction of approximately 40% in the number of daily visits from March to August in 2020 at the emergency sector of the Banco de Olhos Hospital in Porto Alegre. In addition to the number of emergency room visits, the reason for consultation also changed: infectious conjunctivitis decreased significantly and gave way to other pathologies.

Before the pandemic, the diagnosis and reassessment of complicated cases, such as the removal of membranes and pseudomembranes, were always part of our routine. However, these

cases have practically disappeared. In the last few months, it has become common to have entire days without even a single case, an unimaginable fact before March of 2020. Although it cannot be gauged with certainty, hand hygiene and awareness of personal objects campaigns, reduction of direct contact with face and eyes, and, especially, social isolation may be responsible for the decline of conjunctivitis cases.

Infectious conjunctivitis has a large impact in public health. They represent the second most common cause of sick leave from work for a period of seven to 10 days in average.² More severe cases may lead to even more temporary leaves from work. Furthermore, long-term sequelae of infectious conjunctivitis such as dry eye and subepithelial corneal infiltrates, despite happening in the minority of cases, may lead to increased morbidity and reduced quality of vision. According to previous studies, conjunctivitis was responsible for 21.1% of all ocular related issues that lead to absence from work in INSS beneficiaries, with an average 38.7 days away from work.² These are very high numbers that could potentially be prevented with basic hygiene and personal care measures.

By contrast, we have noticed an increase in the number of visits caused by blunt ocular trauma and ocular foreign body, as well as anterior segment repair surgeries caused by penetrating trauma. We have observed that, in many cases, the accidents occurred when performing activities and/or small repairs at home. Nevertheless, Du and collaborators¹ reported a decline in the number of emergency surgeries related to ocular trauma during the critical period of

“In addition to the number of emergency room visits, the reason for consultation also changed: infectious conjunctivitis decreased significantly and gave way to other pathologies”

the pandemic, and hypothesized the reasons to be self-isolation and reduced exposure to environmental risk factors.

Another change that called the team's attention was the number of patients with neurological condition in the Ophthalmology emergency department. The number of visits for cranial nerve pairs paralysis in the months from March to August 2020 more than doubled compared to the same period in 2019, creating challenges in the management and in the referral of these patients. Although it cannot be affirmed, the increased influx of patients with neurological conditions may have been motivated by fear and by the difficulty that these patients were facing in accessing general hospitals. Several times, we have treated patients with diplopia and other systemic motor deficits who chose to report to the ophthalmologist as their first option.

After the initial critical period and as we created a "new normal", there was a gradual resumption of services, especially over the last few months of 2020. We feel that hygiene measures are being effective, and infectious cases

remain low compared to any prior period. In fact, talking to our colleagues in other areas of Brazil and around the world, we have discovered an increase in the number of cases of non-granulomatous anterior uveitis and retina vascular disorders such as Branch or Central Retina Vein Occlusion. Furthermore, a different profile has emerged: chronic and/or gravely ill patients who have delayed their regular appointments either because of difficulties in access or because of the option of patient isolation itself. These cases manifest mainly through diabetic retinopathy, complicated retinal detachments, advanced glaucoma, and unmanaged uveitis.

At this time, we are experiencing another critical period: the number of cases are rising, and elective appointments and surgeries are being cancelled. Therefore, the coming months will still be uncertain and will require precaution; the ophthalmology emergency will remain an entryway and refuge for the most diverse types of patients, but it also needs to support the return of elective care for critically ill patients in order to avoid having an even greater impact

on their ocular health and their quality of life. The second peak of the disease is already a reality, and we are committed to encouraging patients in need of treatment to seek the services and to follow the recommended care measures.

A FINAL MESSAGE TO READERS

A big question that only time will show us is whether we will be able to maintain the awareness of hygiene and if we will be able to avoid other infectious diseases. We have tools that have proven themselves effective, and we are facing mass awareness. Is this our great lesson? I wish it were.

Acknowledgments to nurse Andrea for collecting data on emergency ophthalmological care during the periods mentioned.

REFERENCES

1. Du H, Zhang M, Zhang H, Sun X. Practical experience on emergency ophthalmic surgery during the prevalence of COVID-19.
2. Veloso JCB, Câmara Filho JWS, Gaete MIL, Lira RPC. Frequency of ocular diseases among recipients of disability benefits in the metropolitan region of Recife, Brazil. *Arq Bras Oftalmol.* 2018;81(4):2020.



Did you know that accessing the journal
Oftalmologia em Foco online is possible even
if you are not a **BRASCRS** member?

Become a **DIGITAL MEMBER**

and stay up to date with news about

Cataract, Refractive, and other specialties!

www.ofthalmologiaemfoco.com

SUMMARY



BRASCRS 2021

XI Brazilian Congress of Cataract and Refractive Surgery
IX Brazilian Congress of Administration in Ophthalmology
IV Course for Ophthalmology Assistants

New date!

AUGUST 18TH TO 21ST

SALVADOR - BRAZIL

www.brascrs2021.com.br

ABCCR
Associação Brasileira de Catarata e Cirurgia Refrativa



BRASCRS
Brazilian Association of Cataract and Refractive Surgery